

Influence of primary stability and osteotomy technique on immediately loaded implants in the maxillary posterior region: An *in vivo* study

➤ I. SINGH¹, M. SHETTY², C. HEGDE³, A. SHETTY⁴, N. JOHN⁴

AB Shetty Memorial Institute of Dental Sciences, Nitte Deemed to be University, Mangaluru, Karnataka, India

¹Prosthodontics and Crown & Bridge

²Head of the Department –Department of Oral Implantology

³Head of the Department- Prosthodontics and Crown & Bridge

⁴Lecturer- Prosthodontics and Crown & Bridge

TO CITE THIS ARTICLE

Singh I, Shetty M, Hegde C, Shetty A, John N. Influence of primary stability and osteotomy technique on immediately loaded implants in the maxillary posterior region: An *in vivo* study. *J Osseointegr* 2022;14(4):246-253.

DOI 10.23805/JO.2022.14.27

KEYWORDS Dental implants, Osseodensification, Immediate loading.

ABSTRACT

Aim The maxillary posterior region is a challenging area to achieve successful osseointegration, specifically for immediately loaded implants due to low density bone. To achieve high primary stability in poor density bone, a new surgical technique for osteotomy preparation known as osseodensification, has been developed. This technique leads to an increase in primary and secondary stability which can be assessed and quantified by resonance frequency analysis.

Materials and methods A total of 24 patients were divided into two groups. The implants (Ankylos® implant, Dentsply, Sirona) in Group 1 were placed using conventional osteotomy and Group 2 implants (Ankylos® implant, Dentsply, Sirona) were placed using osseodensification technique in the maxillary posterior region. The stability was assessed at the time of implant placement, at three months and six months with the aid of resonance frequency analysis (Osstell). For the statistical analysis repeated measure ANOVA and Bonferroni Pairwise comparison were used to compare the ISQ (Implant stability quotient) within each group.

Results There was a statistically significant difference observed in the ISQ values at the time of placement, three months and six months after implant placement in Group 1 while the difference in the ISQ values in Group 2 was not significant.

Conclusions Implants placed with osseodensification technique showed consistent stability values in a period of six months. Thus, osseodensification technique can be used to achieve high primary stability of immediately loaded implants in the maxillary posterior region.

INTRODUCTION

Implant treatment has been associated with excellent clinical outcomes leading to their extensive use. For successful treatment, osseointegration of implant is primary requisite. Reduced bone density in the maxillary posterior region, can adversely affect osseointegration, consequently affecting primary and secondary stability. Various techniques such as osteotome techniques and undersized osteotomy have been used to achieve higher primary stability in low-density bone. Such techniques commonly led to pressure bone necrosis, hindering secondary implant stability or osseointegration (1-3). Therefore, a new osteotomy preparation technique, osseodensification, has recently been developed. Densifying burs are specifically designed burs which function in a non-subtractive method. They operate in a drilling process that allows bone preservation and autografting compaction. Osseodensification has shown to improve the quality and quantity of the bone around the implants which is linked to successful osseointegration. The bone condensation technique maintains a large volume of the existing bone, thus optimizing the primary stability of implants in a low density bone. Therefore, this study aims to evaluate the effect of the osseodensification technique in comparison to the conventional osteotomy technique on the primary stability of immediately loaded implants in the posterior maxillary region.

MATERIALS AND METHODS

Patient recruitment

The study design and protocol were approved by the

Institutional Ethics Committee of ABSMIDS Nitte University (Cert. No. ABSM/EC28/2017). The study was conducted with strict adherence to the guidelines of the Helsinki Declaration of 1964 (revised in 2013). A total of 24 patients missing single maxillary posterior teeth were included in the study.

Sample size (n) was estimated using the formula:

$$n = \frac{Z^2(1 - \frac{p}{2}) \times P \times Q}{d^2}$$

Patients were enrolled from the outpatient department and were individually informed about the nature of the study and their participation for a period of 182 days. All patients signed a written informed consent.

Inclusion criteria were the following.

- Adequate bone height and width for implant placement in maxillary posterior regions.
- Sufficient bone volume without the need for bone augmentation procedures.
- Healed maxillary edentulous region.

Exclusion criteria were the following.

- Uncontrolled diabetes mellitus.
- Hypertension.
- Hard and soft tissue pathology.
- Use of medications detrimental to the process of healing.
- Harmful oral habits such as smoking and bruxism.
- Presence of any active infection.
- Limited mouth opening.

Methodology

A pre-operative orthopantomograph (OPG) and pre assessment of the region was performed. The study individuals were divided through random sampling technique into two groups, with each group composed of 12 patients. Group 1 received implants using the conventional osteotomy technique and Group 2 received implants using the osseodensification technique for osteotomy preparation.

Conventional osteotomy technique was performed using Ankylos drills in a standardised protocol according to manufacturer's instructions. The osseodensification technique for osteotomy preparation was performed using Densah burs, provided by the Versah company (Fig. 1). These burs are to be used with a standard surgical engines in a counterclockwise direction to condense and preserve bone at a speed of 800-1500rpm. Care is taken to select the appropriate bur sequence for osteotomy preparation as indicated by the implant type (straight/tapered), implant diameter and bone density (dense/soft).

Surgical phase

A prophylactic antibiotic therapy (Amoxicillin 500mg+Clavulanate 125 mg) was administered to the patient before the procedure (i.e. the previous night and on the day of the procedure) as per Misch's Protocol. Patients were advised to continue with antibiotic therapy for five days. Patients were to begin analgesic



FIG. 1 Densah bur kit for osseodensification.

treatment instantly after operation (ibuprofen 400mg + paracetamol 325 mg) 2 days before surgery, 0.12 percent chlorhexidine gluconate mouthwash was also recommended.

The patient was prepared for the procedure by means of a povidone-iodine solution (Ramadine 5%; Raman And Well, India) that acts as a disinfectant. Surgery was performed using Lignospan special (2% lidocaine with 1:80,000 adrenaline) (Septodont) for local infiltration anesthesia. A mid-crestal incision was made and a mucoperiosteal flap of full thickness was raised. In group 1, sequential drills were used according to the manufacturer's drilling sequence for osteotomy preparation for the implant system. While in Group 2, the osteotomy preparation was done using Densah burs in the recommended sequence.

The length and diameter of the implant to be placed were based on the pre-evaluated availability of bone height and width at a speed of 25Ncm estimated by a physio dispenser. Implant stability quotients were evaluated with the aid of the Osstell Mentor unit immediately after implant placement to assess the resonance frequency analysis (RFA) for establishment of implant stability quotient (ISQ) (Fig. 2A, 2B). A smart peg is attached to the implant and ISQ was recorded (Fig. 3). Following the ISQ measurement, an abutment was placed and torqued manually. A provisional prosthesis of temporary acrylic resin material (3 M ESPE, Protemp 4) was cemented.

The abutments were untorqued at each follow-up session, three months and six months after implant placement, for ISQ assessment. The smartpeg was re-inserted and stability was evaluated, accompanied by radiographic evaluation. Patient was recalled for the prosthetic phase six months after surgery. Pre and post-operative OPGs of each group were compared (Fig. 4, 5).

Statistical analysis

Data was analysed with SPSS version 2.2. Descriptive statistics mean, standard deviation were calculated. Unpaired t test between the two techniques was

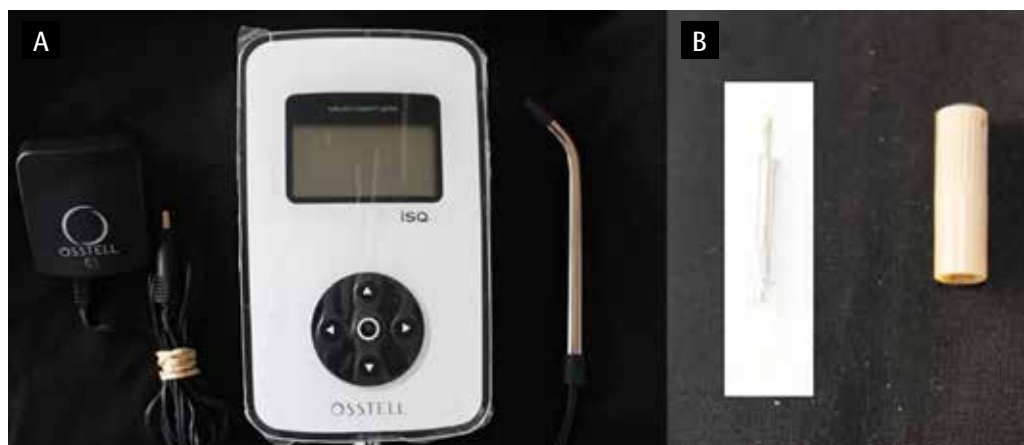

FIG. 2A,2B Ostell mentor device (A) SmartPeg and Transfer cap (B).

performed. Paired t test was used to find differences between buccal and palatal region. Repeated measures ANOVA was used to find difference within the groups in buccal and palatal in the two techniques. $P < 0.05$ was considered significant.

RESULTS

All implants were non functionally loaded and assessed after 3 months and 6 months. The implants were 100% successful and at 6 months were functionally loaded with physiologic occlusion.

The comparison of implant stability quotient values between the two techniques at time of placement, 3 months and 6 months after with respect to buccal and palatal region, showed that the mean ISQ values were not significant in between the two groups (Table

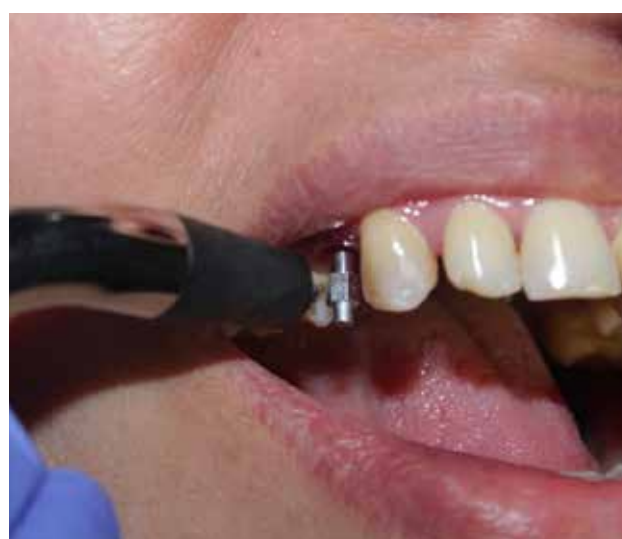

FIG. 3 Measurement of ISQ with smartpeg.

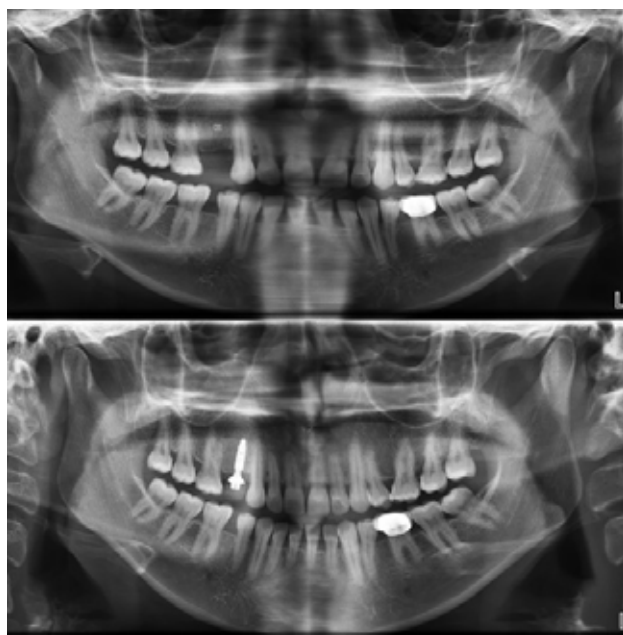


FIG. 4 Preoperative (top) and postoperative (bottom) OPG of group 1.

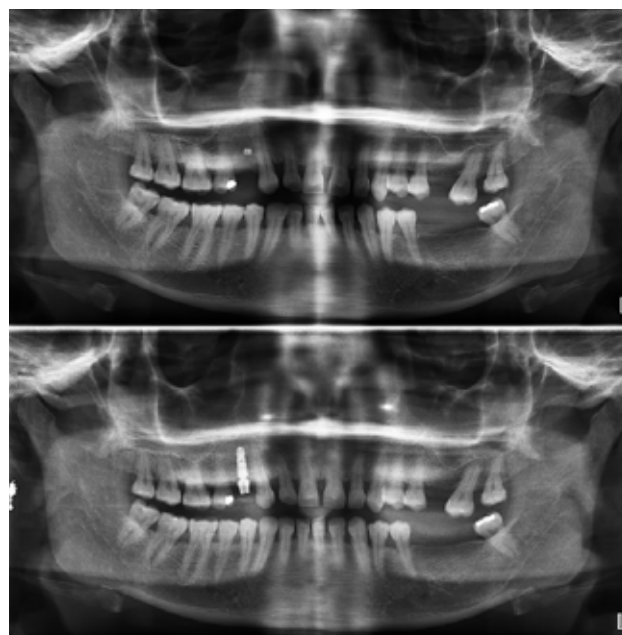


FIG. 5 Preoperative (top) and postoperative (bottom) OPG of group 2.



1, 2). The comparison of ISQ values between buccal and palatal area in Group 1 (where implants were placed with conventional osteotomy technique), the mean ISQ values were not significant (Table 3). The comparison of ISQ values between buccal and palatal region in Group 2 (where implants were placed with osseodensification technique), the mean ISQ values showed no statistically significant difference (Table 4). Repeated measures ANOVA was used to find differences within the groups in buccal region with the two

techniques. Overall, there was a statistically significant difference in the three intervals. To find exactly which group differed, the Bonferroni multiple comparison test was used. Significant differences were observed in buccal and palatal regions from baseline vs 3 months, baseline vs 6 months and 3 months to 6 months ($P < 0.05$) in conventional osteotomy group. No significant difference was observed in buccal and palatal regions from baseline vs 3 months, baseline vs 6 months and 3 months to 6 months in Group 2 (osseodensification) (Table 5, 6).

	Group	N	Mean	Std. Deviation	t	P	95% Confidence Interval of the difference	
							Lower	Upper
Buccal at time of placement	Conventional osteotomy	12	72.00	5.394	-.391	0.701	-9.099	6.265
	Osseodensification	12	73.42	11.317				
Buccal at 3 months	Conventional osteotomy	12	69.92	5.791	-1.920	0.068	-9.533	.366
	Osseodensification	12	74.50	5.901				
Buccal at 6 months	Conventional osteotomy	12	74.75	4.495	.281	0.781	-4.785	6.285
	Osseodensification	12	74.00	8.079				

a N- Sample size, Std. deviation- Standard deviation Statistically insignificant difference compared to baseline

TABLE 1 Comparison of implant stability quotient values in the buccal region between the two techniques at time of placement, after 3 months and 6 months.

	Group	N	Mean	Std. Deviation	t	P	95% Confidence Interval of the difference	
							Lower	Upper
Palatal at time of placement	Conventional osteotomy	12	72.00	5.274	-.203	0.842	-8.621	7.121
	Osseodensification	12	72.75	11.678				
Palatal at 3 months	Conventional osteotomy	12	69.58	5.760	-2.013	0.056	-9.474	.140
	Osseodensification	12	74.25	5.594				
Palatal at 6 months	Conventional osteotomy	12	74.25	4.634	.195	0.847	-4.813	5.813
	Osseodensification	12	73.75	7.569				

aN- Sample size, Std. deviation- Standard deviation Statistically insignificant difference compared to baseline

TABLE 2 Comparison of implant stability quotient values in the palatal region between the two techniques at the time of placement, after 3 months and 6 months.

	Mean	Std. Deviation	t	P	95% Confidence Interval of the difference	
					Lower	Upper
Buccal at time of placement	72.00	5.394	0	1	-.271	.271
Palatal at time of placement	72.00	5.274				
Buccal at 3 months	69.92	5.791	1.773	0.104	-.081	.747
Palatal at 3 months	69.58	5.760				
Buccal at 6 months	74.75	4.495	1.483	0.166	-.242	1.242
Palatal at 6 months	74.25	4.634				

*Std. deviation- Standard deviation Statistically insignificant difference compared to baseline

TABLE 3 Comparison of ISQ values between buccal and palatal in Group 1 (conventional osteotomy).

	Mean	Std. Deviation	t	P	95% Confidence Interval of the difference	
					Lower	Upper
Buccal at time of placement	73.42	11.317	1.076	0.305	-.697	2.030
Palatal at time of placement	72.75	11.678				
Buccal at 3months	74.50	5.901	0.376	0.714	-1.212	1.712
Palatal at 3months	74.25	5.594				
Buccal at 6months	74.00	8.079	0.561	0.586	-.732	1.232
Palatal at 6months	73.75	7.569				

Std. deviation- Standard deviation

Statistically insignificant difference compared to baseline

TABLE 4 Comparison of ISQ values between buccal and palatal region in Group 2 (osseodensification).

Within-Subjects Factors	
Factor 1	Dependent Variable
1	Buccal at time of placement
2	Buccal at 3 months
3	Buccal at 6 months

Group = Conventional osteotomy

	Mean	Std. Deviation	N
Buccal-at time of placement	72.00	5.394	12
Buccal at 3 months	69.92	5.791	12
Buccal at 6 months	74.75	4.495	12

F= 27.248 P<0.001

group = Osseodensification

	Mean	Std. Deviation	N
Buccal at time of placement	73.42	11.317	12
Buccal at 3 months	74.50	5.901	12
Buccal at 6 months	74.00	8.079	12

F=.083 P=0.920 ns

Multiple comparisons: Bonferroni

(I) factor1	(J) factor1	Mean difference (I-J)	P	95% Confidence Interval for difference	
				Lower Bound	Upper Bound
1	2	2.083*	0.045	.046	4.121
	3	-2.750*	<0.001	-4.055	-1.445
2	3	-4.833*	<0.001	-6.940	-2.727

*The mean difference is significant at the .05 level.

TABLE 5 Comparison within the buccal region at baseline, 3 months and 6 months after.

DISCUSSION

With increase in patient knowledge and expectations along with the need for faster treatment, immediate loading protocol was introduced to offer esthetic, psychologic and functional restoration to the patient. This loading protocol is followed in various cases of

Within-Subjects Factors

Factor 1	Dependent Variable
1	Palatal at time of placement
2	Palatal at 3 months
3	Palatal at 6 months

Group = Conventional osteotomy

	Mean	Std. Deviation	N
Palatal at time of placement	72.00	5.274	12
Palatal at 3 months	69.58	5.760	12
Palatal at 6 months	74.25	4.634	12

F=21.805 P<0.001

Group = Osseodensification

	Mean	Std. Deviation	N
Palatal at time of placement	72.75	11.678	12
Palatal at 3 months	74.25	5.594	12
Palatal at 6 months	73.75	7.569	12

F=0.160 P=0.853

Multiple Comparisons: Bonferroni

(I) factor1	(J) factor1	Mean difference (I-J)
1	2	2.417*
	3	-2.250*
2	3	-4.667*

*. The mean difference is significant at the .05 level.

TABLE 6 Comparison within the palatal region at baseline, 3 months and 6 months after.

single or multiple implants. A micromotion of 50–150 μm is considered as a threshold to achieve osseointegration. Beyond this threshold, deleterious micromovement occurs which may cause implants to be surrounded with fibrous tissue, thus preventing osseointegration (1,6).

A high primary stability is an essential prerequisite for immediate loading of implants. Various factors such as implant dimension, design of the implant, micromorphology of the implant surface, implant placement technique and congruity between the implant and the surrounding bone are said to influence primary stability. Alteration in stability has been observed with new bone formation and remodeling. This may further be affected by the quality/density of the bone.

Low-density bone implant sites have been identified, with standard osteotomy technique, as one of the greatest potential risk factors affecting implant treatment outcome. A clinical study with implants that were immediately loaded showed higher failure rate in low density bones, which confirmed the idea that primary stability is an essential determinant for the success of immediately loaded implants (7–10).

To overcome the challenge of achieving high primary stability, Summer described a technique of condensing the bone using osteotomes. Though the density of the peri-implant bone reportedly increased, the method was complex and required additional surgical skills to ensure success; also incidence of microfractures in the peri-implant bone were seen in comparison with a conventional drilling method (9–14).

Another surgical approach used to achieve greater implant stability was undersizing of osteotomy. Several *in vitro* and *in vivo* studies have shown increased insertion torque values during implant placement in undersized implant beds, an approach also coined as underpreparation (15).

Implants placed with underpreparation protocol showed statistically significantly lower amount of bone to implant contact at the coronal aspect. This can be attributed to the already under strain bone, due to underpreparation, being exerted additional strain from immediate loading at the peri-implant bone tissue, which can interfere with the reparatory processes of bone remodeling during early peri-implant wound healing phase, especially at the coronal aspect of the implants (15).

To prevent such complications, it was necessary to develop specific drilling sequences, adapted to the implant designs and dimensions to provide high primary stability and low strain to the surrounding bone. A new technique was proposed called osseodensification. This technique works on bone preservation protocol and is carried out using a specially designed bur. The bur has a large negative rake angle and many spiral guides called lands works as non-cutting edge and thus increases the density of the bone as the osteotomy is expanded. Their design incorporates a cutting chisel edge and a tapered shank, therefore their progressively increasing

diameter tends to control the expansion process as the osteotomy is deepened (16).

A standard surgical engine is used to run the burs (800–1200 rpm) and they can be used in clockwise direction for cutting or drilling of the bone and in counterclockwise or non-cutting direction for densifying the bone. Copious amount of irrigation fluid and bouncing motion of the bur during osteotomy preparation is recommended. This induces a pressure wave and the forced irrigation fluid into the osteotomy makes it easier to autograft the bone particles throughout the internal osteotomy surface.

The new technique compacted the bone by using controlled deformation due to rolling and sliding contact along the osteotomy's inner surface with the rotating lands of the densifying bur. The autografting of the bone particles supplements this densification with the inner wall of the osteotome. An opposing axial reaction force during the bur to bone contact is said to be proportional to the intensity of the force applied by the surgeon, this makes the densifying procedure to be a safely controlled technique. Also, this provides a haptic feedback which helps in controlling the force based on the bone density encountered and facilitate controlled plastic deformation thus compacting the bone and expanding the osteotomy (16).

An environment of high primary stability, because of compaction autografting and the existence of remaining bone chips, is achieved by the osseodensification drilling technique. In addition, bone densification also speeds up new bone growth via osteoblast nucleation of the instrumented bone, thus increasing the bone to implant contact (3).

There are various methods which can quantify and assess the primary stability of the implant achieved, thus helping in evaluating the osseointegration of the implants. Subjective methods such as percussion test and invasive test such as removal torque test have been also used, however, their invasive nature and unpromising result have discouraged their clinical use. A quantitative method, Periotest system, also assesses implant stability however it was not sensitive to differentiate between osseointegrated and non-osseointegrated implants. A non-invasive clinical method described by Meredith et al was the resonance frequency analysis (RFA) (17).

RFA applies a small bending load which tends to imitate the clinical load and direction thus measuring the stability and providing information on implant-bone connection stiffness. Three main factors influence the resonance frequency in the resonance frequency analysis method: firstly, the design of the transducer; secondly is the rigidity and interface of the tissues to the bone surroundings of the implant fixture, and thirdly, the total length effective above the bone level.

Since 1999, the Integration Diagnostics Ltd. Company (Sävedalen, Sweden) have been designing a non-invasive diagnostic tool, Osstell, to measure implant stability clinically and with ease, with several generations of the

device already being developed. The latest generation, Ostell ISQ includes a new control unit with a cable linked probe. Another advantage of the latest generation is the pre calibrated transducer provided by the manufacturers, which increases the ease of its practice clinically (17).

The present study included a total of 24 patients divided into two groups of 12 each. Group 1 received implants (Ankylos®. Dentsply) using a conventional osteotomy technique, while Group 2 received implants (Ankylos®. Dentsply) using osseodensification protocol via Densah burs. Implant stability was then assessed at baseline, 3 months and at 6 months using RFA.

In group 1, the mean ISQ value achieved was 72.00 ± 5.394 buccally and 72.00 ± 5.274 palatally at the time of placement which was appreciable for immediate loading as suggested by previous studies.

After three months, the mean ISQ value obtained was 69.92 ± 5.791 buccally and 69.58 ± 5.760 palatally in group 1, which showed significant decrease in the stability question in comparison to the baseline value. This result obtained was in relation to the study conducted by Glauser et al., where the implant stability quotient dropped at 3 months due to the extensive remodeling that takes place (18).

The mean ISQ values after 6 months were 74.75 ± 4.495 buccal and 74.25 ± 4.634 palatal, which indicated that the clinical stability was restored after the initial remodeling phase.

The mean ISQ values between Group 1 and Group 2 at baseline, three months and six months follow up showed similar results and there was no significant difference observed between the two groups.

In Group 2, the mean ISQ values 73.42 ± 11.317 buccally and 72.75 ± 11.678 palatally were achieved at the time of placement. These values were slightly higher in comparison to Group 1, though they were not statistically significant. Due to the high stability achieved, the immediate loading protocol was carried forward.

The mean ISQ values obtained in Group 2 buccally at 3 months and 6 months were 74.50 ± 5.901 and 74.00 ± 8.079 respectively. There was no decrease in the stability of the implants placed in Group 2. Also, there was a significant difference in the ISQ values in both buccal and palatal region in Group 1, while there was no significant difference in Group 2. This indicates that the stability of the implants was maintained throughout the remodelling phase in Group 2.

In the study conducted by Huwais et al., there was a reduction in the diameter of osteotomy to approximately 91% of the bur diameter, assessed using microcomputed tomography imaging, when the osseodensified osteotomy was left empty (19,20).

Therefore, the viscoelastic recovery due to the residual strains created in the bone due to the osseodensification technique create compressive forces against the implants. This can be an attributed reason for the maintained primary stability seen in Group 2.

The present study reveals the consistency in the high primary stability achieved due to osseodensification technique for implant placement. Thus, it can be concluded that the osseodensification technique can be a method to achieve a high primary stability in the maxillary posterior region and to ensure the success of immediately loaded implants in low density bone such as maxillary posterior region.

More *in vivo* studies are needed to evaluate with a larger sample size and a longer follow up period with standardisation in the bone density.

CONCLUSION

Within the limitations of the study, it can be concluded that the osseodensification technique can be a method to achieve a high primary stability in the maxillary posterior region and to ensure the success of immediately loaded implants in low density bone.

Financial support

None.

Conflicting Interest

None.

REFERENCES

1. Nkenke E, Fenner M. Indications for immediate loading of implants and implant success. *Clin Oral Implants Res* 2006 Oct;17 Suppl 2:19-34.
2. Oliveira PGFP, Bergamo ETP, Neiva R, Bonfante EA, Witek L, Tovar N, Coelho PG. Osseodensification outperforms conventional implant subtractive instrumentation: A study in sheep. *Mater Sci Eng C Mater Biol Appl* 2018 Sep 1;90:300-307.
3. Lahens B, Lopez CD, Neiva RF, Bowers MM, Jimbo R, Bonfante EA, Morcos J, Witek L, Tovar N, Coelho PG. The effect of osseodensification drilling for endosteal implants with different surface treatments: A study in sheep. *J Biomed Mater Res B Appl Biomater* 2019 Apr;107(3):615-623.
4. Swami V, Vijayaraghavan V, Swami V. Current trends to measure implant stability. *J Indian Prosthodont Soc* 2016 Apr-Jun;16(2):124-30.
5. Bischof M, Nedir R, Szmukler-Moncler S, et al. Implant stability measurement of delayed and immediately loaded implants during healing. A clinical resonance-frequency analysis study with sandblasted-and-etched ITI implants. *Clin Oral Implants Res* 2004 Oct;15(5):529-39.
6. Proussaefs P, Kan J, Lozada J, Kleinman A, Farnos A. Effects of immediate loading with threaded hydroxyapatite-coated root-form implants on single premolar replacements: a preliminary report. *Int J Oral Maxillofac Implants* 2002 Jul-Aug;17(4):567-72.
7. Jacobs R. Preoperative radiologic planning of implant surgery in compromised patients. *Periodontol* 2000 2003 Oct;33(1):12-25.
8. Grant BT, Kraut RA. Dental implants in geriatric patients: a retrospective study of 47 cases. *Implant Dent* 2007 Dec;16(4):362-8.
9. Alghamdi H, Anand PS, Anil S. Undersized implant site preparation to enhance primary implant stability in poor bone density: a prospective clinical study. *J Oral Maxillofac Surg* 2011 Dec;69(12):e506-12.
10. Glauser R, Réé A, Lundgren A, Gottlow J, Hämmeler CH, Schärer P. Immediate occlusal loading of Brånemark implants applied in various jawbone regions: a prospective, 1-year clinical study. *Clin Implant Dent Relat Res* 2001;3(4):204-13.

11. Javed F, Romanos GE. The role of primary stability for successful immediate loading of dental implants. A literature review. *J Dent* 2010 Aug 1;38(8):612-20.
12. Summers RB. A new concept in maxillary implant surgery: the osteotome technique. *Compendium (Newtown, Pa.)*. 1994 Feb;15(2):152-4.
13. Büchter A, Kleinheinz J, Wiesmann HP, et al. Biological and biomechanical evaluation of bone remodelling and implant stability after using an osteotome technique. *Clin Oral Implants Res* 2005 Feb;16(1):1-8.
14. Podaropoulos L. Increasing the stability of dental implants: The concept of osseodensification. *Balk J Dent Med* 2017 Nov 27;21(3):133-40.
15. Stavropoulos A, Cochran D, Obrecht M, Pippenger BE, Dard M. Effect of Osteotomy Preparation on Osseointegration of Immediately Loaded, Tapered Dental Implants. *Adv Dent Res* 2016 Mar;28(1):34-41.
16. Trisi P, Berardini M, Falco A, Podaliri Vulpiani M. New Osseodensification Implant Site Preparation Method to Increase Bone Density in Low-Density Bone: In Vivo Evaluation in Sheep. *Implant Dent* 2016 Feb;25(1):24-31.
17. Herrero-Climent M, Santos-García R, Jaramillo-Santos R, Romero-Ruiz MM, Fernández-Palacin A, Lázaro-Calvo P, Bullón P, Ríos-Santos JV. Assessment of Osstell ISQ's reliability for implant stability measurement: a cross-sectional clinical study. *Med Oral Patol Oral Cir Bucal* 2013 Nov 1;18(6):e877-82.
18. RGlauer R, Sennerby L, Meredith N, Rée A, Lundgren A, Gottlow J, Hämmerle CH. Resonance frequency analysis of implants subjected to immediate or early functional occlusal loading. Successful vs. failing implants. *Clin Oral Implants Res* 2004 Aug;15(4):428-34.
19. Huwais S, Meyer EG. A Novel Osseous Densification Approach in Implant Osteotomy Preparation to Increase Biomechanical Primary Stability, Bone Mineral Density, and Bone-to-Implant Contact. *Int J Oral Maxillofac Implants* 2017 Jan/Feb;32(1):27-36.
20. Kold S, Bechtold JE, Ding M, Chareancholvanich K, Rahbek O, Søballe K. Compacted cancellous bone has a spring-back effect. *Acta Orthop Scand* 2003 Oct;74(5):591-5.