

Outcomes evaluation of a patient treated with roots immediate digital denture: patient evaluation after full digital dentures

➤ A. CASUCCI^{1*}, G. VERNIANI^{1**}, L. F. D'ARIENZO^{1***}, A. KEELING², M. FERRARI^{1****}

¹Department of Prosthodontics, University of Siena, Siena, Italy

* DDS, PhD ** DDS *** DDS, MSc **** MD, DMD, PhD

²BSc, BDS, MFGDP, PhD, Department of Restorative Dentistry, School of Dentistry, University of Leeds, Leeds, United Kingdom

TO CITE THIS ARTICLE

Casucci A, Verniani G, D'Arienzo LF, Keeling A, Ferrari M. Outcomes evaluation of a patient treated with roots immediate digital denture: Patient evaluation after full digital dentures. *J Osseointegr* 2024; 16

DOI 10.23805/JO.2024.616

KEYWORDS Edentulous treatment, intraoral scanner, immediate denture, digital workflow, root over denture

ABSTRACT

The immediate dentures fabrication in the analogic manner may be an high time-consuming and unreliable procedure. The purposes of this article were both to describe a simplified protocol based on a digital workflow used to fabricate a set of immediate dentures and to report patient functional and quality of life data. The digital intraoral scans were recorded and used for dentures design, the teeth arrangement proposed by the software was superimposed to patient frontal photo in order to simulate the aesthetic proposal. The resulted Standard Tessellation Language files were exported to a milling machine for denture fabrication. After immediate denture delivery the remaining lower canine roots were used to retain the prosthesis. In order to evaluate the different effects of the treatment on masticatory efficiency, bite force and health-related quality of life (OHRQoL) data were measured before and after treatment. The patient reported a good adaptation form the delivery, an improvement for all the aspects evaluated after prostheses roots anchorage.

INTRODUCTION

When the complete arches extraction is required, the patient, becoming edentulous, may experience social, psychological and aesthetic consequences. To avoid these impairment conditions the fabrication of immediate dentures (ID) before the extractions can be provided(1). Anyway, the transition from the remaining teeth to a removable solution can be a challenge for the patient due to the lack of retention and stability. For this reason, when it is possible, leaving supporting roots can improve the patient's performance with immediate denture and

facilitate adaption. Different procedures have been described to provide an ID(2,3,4), but in all the conventional methods a lot of appointments and laboratory time are required(5). Recently, computer-aided design and computer-aided manufacturing (CAM-CAM) technology has been used to fabricate complete dentures(6,7). It was reported that Digital Dentures (DD) can provide improved denture retention and fit(8,9), a time reduction of both clinical and laboratory procedures(10), higher patient satisfaction(11), and reduced costs compared to analogic protocols(12). Most clinicians still use conventional procedures for impressions and occlusal recording that are then digitized in the laboratory(13,14), however, it can determine a reduced precision of prostheses due to the several steps required. Recently it was reported that the intraoral scanners (IOS) may be accurate for complete denture fabrication(15-19). The use of this technology has allowed to minimize the inconveniences associated with the use of traditional impression materials(20). The mobility of the remaining teeth would not allow easy removal of the impression tray without exposing the patient to the risk of avulsions. Additionally, the digital software design allows to simulation of the aesthetic proposal thanks to the possibility of superimposing additional IOS (temporaries or old dentures) face scans or patient face photos. The predictability of these digital options is still updated and is not fully documented in the scientific literature, for this reason, it was chosen to report this clinical case to evaluate the correspondence of the aesthetic results obtained from digital design software to patient mouth through immediate denture treatment.

To date, few studies reported a strong influence of dental loss over the masticatory efficiency and maximal bite force(21), but the improvement it with different prosthetic treatment options has been confirmed(22). In these studies




FIG. 1
Extraoral photos:
A and C: lateral view
B: frontal view

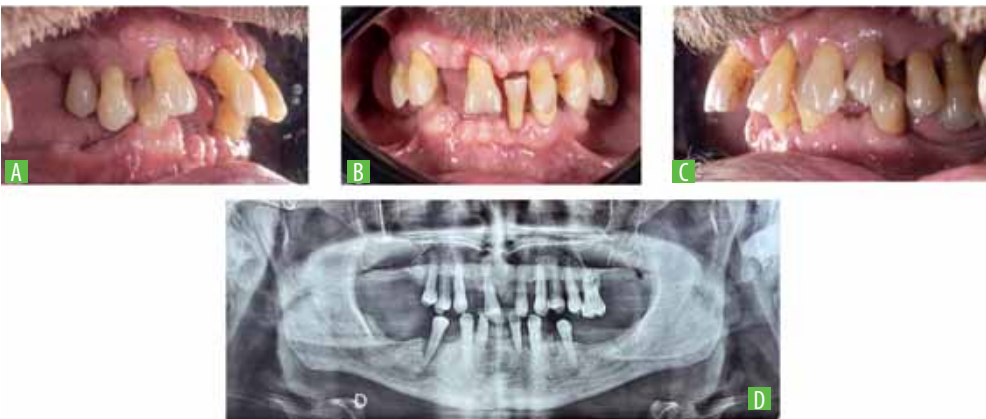


FIG. 2
A-C: Intraoral photos
D: panoramic radiograph.

the masticatory efficiency was evaluated using the two-coloured gums test proposed by Schimmel(23) and the bite force was recorded using a novel device called Innobyte (Kube Innovation, Montreal, Canada). Both aspects were registered at different phases of the treatment: at the beginning with the patient's terminal dentition, 3 weeks after immediate digital denture delivery and finally 3 months after the placement of attachment systems on the lower canines roots.

CLINICAL REPORT

A 58-year-old man presented in the Prosthodontics Department of the University of Siena with terminal

dentition (Fig. 1). The patient was classified as ASA II due to treated hypertension.

Clinical examination and radiographic assessment revealed an unrestored mouth due to severe periodontitis and several non-restorable teeth to support a prosthetic rehabilitation (Fig. 2).

He has been diagnosed with an IV-level generalized periodontitis with more than 70% periodontal attachment loss. Facial, dento-labial and phonetic analyses were performed. The parallelism between the commissural line was evaluated on the facial plane, as well as the relationship between the e-line and lips on the sagittal plane. The patient showed an altered pattern of incisal plane and midline. The remaining upper teeth were extruded and proclined

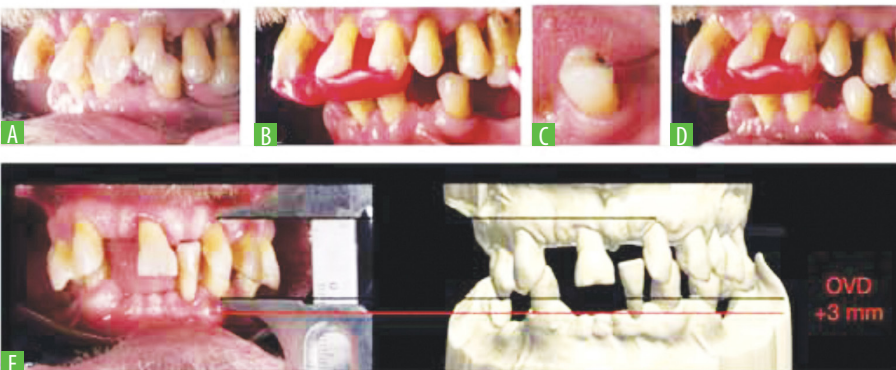


FIG. 3
A-D: Centric position recording
steps
E: OVD increase

	Pre-treatment	3 weeks after delivery	3 month after roots anchorage
Ohip-14	39	25	9
Bite force	167	219	359
Masticatory performance	0.089	0.086	0.05

TABLE 1

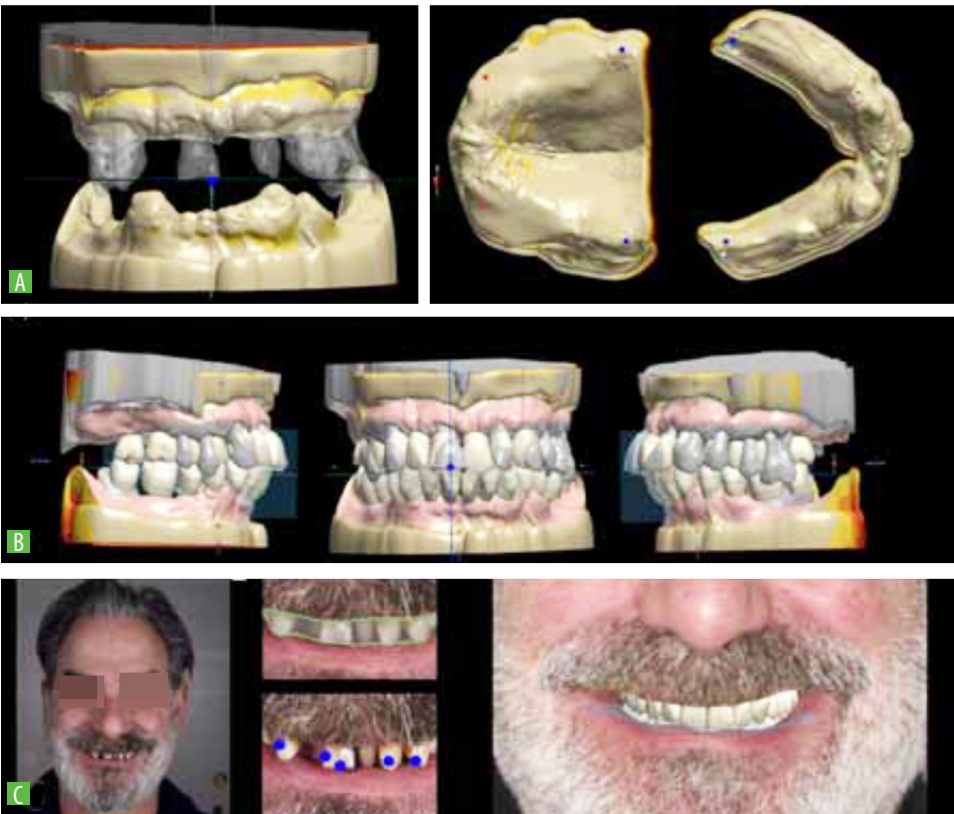


FIG. 4
A: Digital models preparation,
B: teeth arrangement
C: superimposition with previous
teeth and patient smile.

resulting in a compromised phonetics. The initial occlusal evaluation revealed a loss of occlusal vertical dimension (OVD) with overreaction of 14 and 26. Absent conditions affecting the temporal-mandibular joints. Patient needs and Quality of life were recorded at the first visit. An oral health-related quality of life (OHRQoL) test, OHIP-14 in the Italian version was administered before treatment. Initial data on the patient's maximum bite force and masticatory function were also recorded. The bite force was analyzed using Innobyte (Kube Innovation, Montreal, Canada) using three 3-second measurements asking the patient to bite on the support. The final reported value of 167N was calculated as the average of the 3 measurements. The masticatory function was assessed through the Masticatory Performance Test (MP) in which individuals chew a standardized portion of test gum for 20 cycles. The uncertain periodontal prognosis and the patient's limited financial resources led to a treatment plan that included extraction of the maxillary and mandibular teeth and delivery of digital immediate removable complete

dentures. Only lower canines were not extracted, in fact, canines were endodontically treated and maintained as supporting roots. Upper and lower arches were restored with ID obtained thanks to a digital approach. After 3 weeks after extraction and delivery of the dentures, the canine roots were prepared for a direct attachments system. The patient after healing had been reevaluated and a definitive treatment plan had been defined from 1 fixed Implant supported rehabilitations, 2 removable implant-supported rehabilitations, and 3 definitive complete dentures with root attachments. The IOS (TRIOS 3Shape A/S, Copenhagen K, Denmark) was acquired using edentulous dedicated retractors (Lo Russo retractors, ELDO S.r.l., Italy). Since the OVD collapsed, it was decided to raise it around 3 mm according to the patient's facial third support, phonetic and aesthetic parameters. The resulting centric position was recorded after selective grinding on the occlusal surface of the 34. The resulting occlusal position was recorded by IOS. A frontal picture of the patient in the "E" sound position was attached to

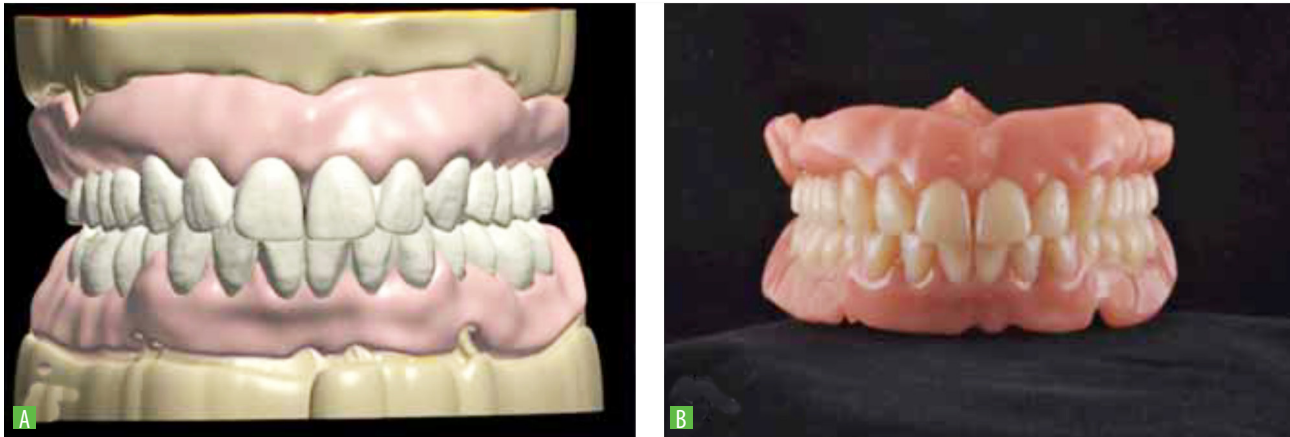


FIG. 5 A-B ID project and finalized prostheses

the scanning data and sent to the laboratory. The obtained data were imported into denture design software (Dental System 2021 3Shape A/S, Copenhagen, Denmark) for ID design. The next step involved the virtual avulsion of dental elements residues resulting in two models of edentulous arches properly oriented in space. The software automatically generated a suggestion for setting up the selected teeth that were selected according to the patient teeth dimension and shape. This setup was customized according to the information obtained by the superimposition of the patient picture in order to evaluate better the esthetic parameters (Fig. 4).

After the designs had been completed for an oversized milling process (Vivadent AG, Ivoclar Vivadent, Schaan, Liechtenstein) PMMA disks for bases and teeth (Ivotion base and Dent multi A3 (Ivoclar Vivadent AG Schaan, Liechtenstein) were selected and positioned inside a five-axis milling unit (PrograMill 7; Ivoclar Vivadent AG, Schaan, Liechtenstein). After the complete milling, the immediate dentures were sent to the office for delivery (Fig. 5). The remaining teeth were extracted according to the treatment

plan and the two lower canines previously endodontic treated, were cut. The set of dentures was immediately inserted after the extractions (Fig. 6). Very good adaptation was found so that no chair-side adjustments were needed. After 7 days the patient reported no pain and we proceeded with soft tissue conditioning (Gc Tissue conditioner, GC, Tokyo Japan). The IDs were anchored after 3 weeks, the patient achieved improved stability and satisfaction. After the healing time of 6 months, thanks to aesthetic and functional results, the patient decided to refuse implants and to maintain the ID relined as a definitive solution (Fig. 7). The data collected for OHRQoL, bite force and masticatory performances were reported at pre-treatment time, 3 weeks after ID delivery and 3 months after root anchorage in the following table (Tab. 1). The two coloured gums images were reported at pretreatment, after delivery and 3 months after roots anchorage (Fig. 8).

DISCUSSION

The purpose of this article was firstly to describe a

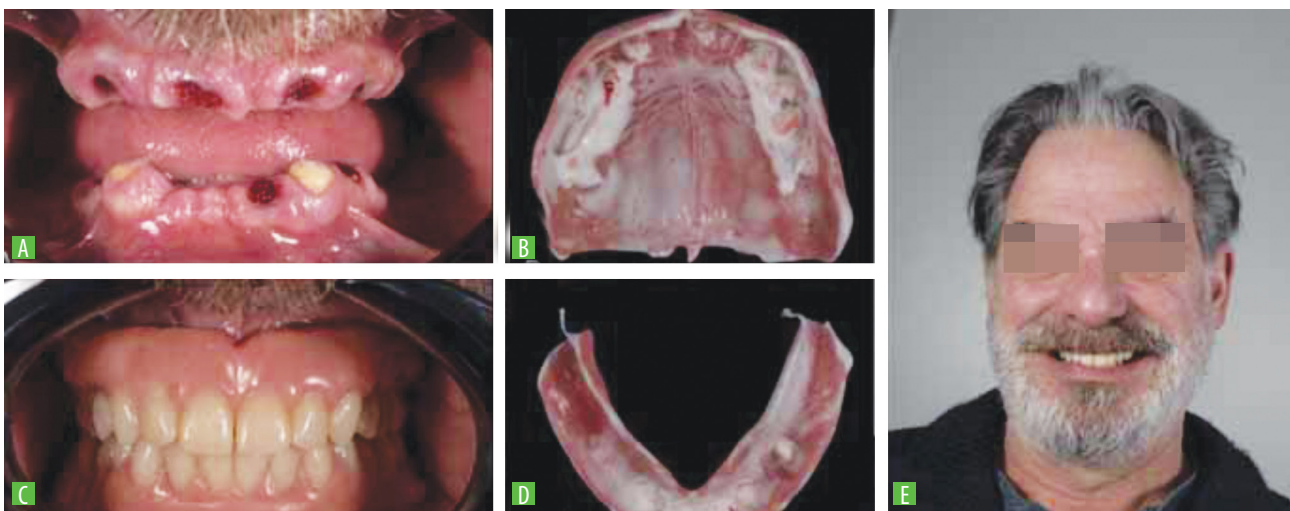


FIG. 6 A intraoral view after teeth extraction, B and D prostheses adaptation evaluation, C and E intramural and extra oral view of the prostheses delivered

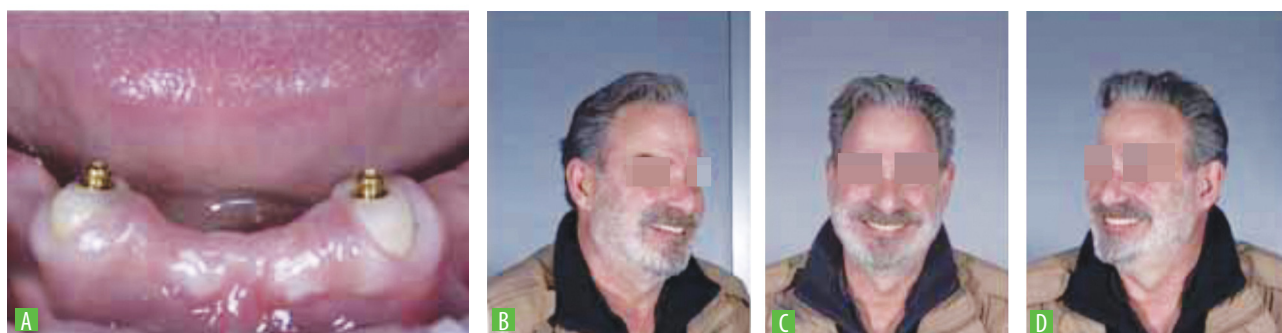


FIG. 7 A Roots attachment systems and B final aesthetics

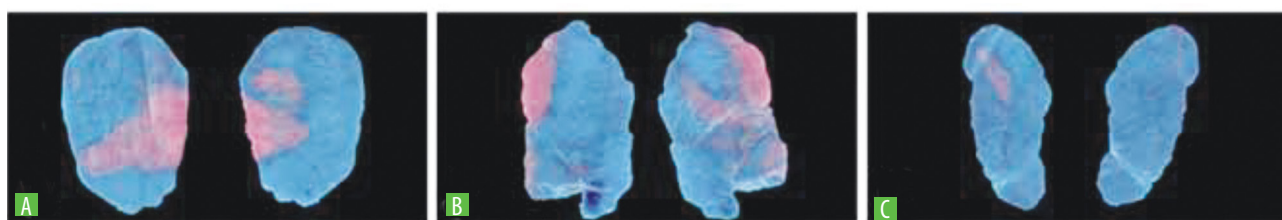


FIG. 8 Gums obtained after 20 masticatory cycles at pretreatment A, after delivery B and 3 months after roots anchorage C.

digital workflow for fabricating immediate dentures before extractions and secondary to report the patient outcomes in terms of OHRQoL, bite force and masticatory performances. All the information was acquired by IOS, the IDs were obtained using DD design software and CAD-CAM technologies. As far as the authors are aware, this is the first published report describing such a technique in a patient with no pre-existing dentures and using a different OVD in the final treatment. The IDs are usually used in situations where the remaining teeth are heavily compromised and loose and the risk of being extracted during conventional impression is high(24).

IOS can be useful to get around this problem and additionally, the images of the teeth are easily cut from the virtual 3D image of the arch without any risk of damaging the cast(25). With conventional ID protocols, registering the inter-maxillary position when the dental support is reduced, as in the presented case, may require a separate appointment from the impression. However, thanks to the bite scan registration predictability, once the new OVD was established in regard to the aesthetic and facial appearance of the patient with wax, it could be registered and exactly reported in the final restoration without any distortion. Additionally, the digital workflow allows to sending of patients' facial images to the laboratory and the technician can individualize the teeth arrangement according to lip lines and extra-oral parameters. In this case report the functional activities were also evaluated. An improvement in maximal bite force was reported in the first weeks after insertion, and a peak after attachments' insertion. Several studies (26-28) demonstrated that the masticatory performance of implant overdenture users increases, likely because the implants improve retention and stability of the mandibular prostheses, but the masticatory performance

of overdentures on natural teeth, as reported in the present case should be better investigated. Additionally in this study, we found an improvement in OHRQoL score for the treated patient starting from terminal dentition, moving to ID and finally with lower overdentures retained by canine roots. The concept of OHQoL is based on the perspective that oral health conditions and diseases can undermine someone's self-esteem and self-image, can cause other health problems, can discourage social interaction, and can lead to pain, stress, or depression(29). One of the goals in dental care is to improve OHQoL of patients and in the reported clinical case this point was reached shortening the operating time and number of appointments thanks to IOS and digital workflow. More clinical studies could be performed in order to validate the clinical results obtained.

CONCLUSION

This article describes a digital workflow that facilitates the fabrication of IDs. The procedure described with roots supported over-denture improved functional and aesthetic parameters improving patient quality of life thanks to a reduced cost protocol. Digital workflow in ID is an innovative promising and predictable procedure that requires more clinical validation.

REFERENCES

1. Gilboa I, Cardash HS. An alternative approach to the immediate overdenture. *J Prosthodont.* 2009 Jan;18(1):71-5.
2. Raczka TC, Esposito SJ. The "jiffy" denture: a simple solution to a sometimes difficult problem. *Compend Contin Educ Dent.* 1995 Sep;16(9):914, 916, 918.

3. Cardash HS, Kaufman C. An interim denture technique. *Quintessence Dent Technol.* 1983 Feb;7(2):89-91.
4. Swoope CC, Depew TE, Wisman LJ, Wands DH. Interim dentures. *J Prosthet Dent.* 1974 Dec;32(6):604-12.
5. Neumeier TT, Neumeier H. Digital immediate dentures treatment: A clinical report of two patients. *J Prosthet Dent.* 2016 Sep;116(3):314-9.
6. Goodacre CJ, Garbacea A, Naylor WP, Daher T, Marchack CB, Lowry J. CAD/CAM fabricated complete dentures: concepts and clinical methods of obtaining required morphological data. *J Prosthet Dent.* 2012 Jan;107(1):34-46.
7. Fang JH, An X, Jeong SM, Choi BH. Digital immediate denture: A clinical report. *J Prosthet Dent.* 2018 May;119(5):698-701.
8. AlHelal A, AlRumaih HS, Kattadiyil MT, Baba NZ, Goodacre CJ. Comparison of retention between maxillary milled and conventional denture bases: A clinical study. *J Prosthet Dent.* 2017 Feb;117(2):233-238.
9. Steinmassl O, Dumfahrt H, Grunert I, Steinmassl PA. CAD/CAM produces dentures with improved fit. *Clin Oral Investig.* 2018 Nov;22(8):2829-2835.
10. Kattadiyil MT, AlHelal A. An update on computer-engineered complete dentures: A systematic review on clinical outcomes. *J Prosthet Dent.* 2017 Apr;117(4):478-485.
11. Kattadiyil MT, Jekki R, Goodacre CJ, Baba NZ. Comparison of treatment outcomes in digital and conventional complete removable dental prosthesis fabrications in a predoctoral setting. *J Prosthet Dent.* 2015 Dec;114(6):818-25.
12. Srinivasan M, Schimmel M, Naharro M, O' Neill C, McKenna G, Müller F. CAD/CAM milled removable complete dentures: time and cost estimation study. *J Dent.* 2019 Jan;80:75-79.
13. Wimmer T, Gallus K, Eichberger M, Stawarczyk B. Complete denture fabrication supported by CAD/CAM. *J Prosthet Dent.* 2016 May;115(5):541-6.
14. Schwindling FS, Stober T. A comparison of two digital techniques for the fabrication of complete removable dental prostheses: A pilot clinical study. *J Prosthet Dent.* 2016 Nov;116(5):756-763.
15. Chebib N, Kalberer N, Srinivasan M, Maniewicz S, Perneger T, Müller F. Edentulous jaw impression techniques: An in vivo comparison of trueness. *J Prosthet Dent.* 2019 Apr;121(4):623-630.
16. D'Arienzo L. F., D'Arienzo A., Borracchini A. (2018). Comparison of the suitability of intra-oral scanning with conventional impression of edentulous maxilla in vivo. A preliminary study. *Journal of Osseointegration,* 10(4), 115–120
17. Lo Russo L, Salamini A, Troiano G, Guida L. Digital dentures: A protocol based on intraoral scans. *J Prosthet Dent.* 2021 Apr;125(4):597-602.
18. Lo Russo L, Salamini A. Removable complete digital dentures: A workflow that integrates open technologies. *J Prosthet Dent.* 2018 May;119(5):727-732.
19. Fang JH, An X, Jeong SM, Choi BH. Digital immediate denture: A clinical report. *J Prosthet Dent.* 2018 May;119(5):698-701.
20. Patzelt SB, Vonau S, Stampf S, Att W. Assessing the feasibility and accuracy of digitizing edentulous jaws. *J Am Dent Assoc.* 2013 Aug;144(8):914-
21. Rosa LB, Semprini M, Siéssere S, Hallak JE, Pagnano VO, Regalo SC. Correlation between bite force and electromyographic activity in dentate and partially edentulous individuals. *Electromyogr Clin Neurophysiol.* 2009 Sep-Oct;49(6-7):291-7.
22. Possebon APDR, Schuster AJ, Bielemann AM, Porto BL, Boscato N, Faot F. Evaluation of Bite Force and Masticatory Performance: Complete Denture vs Mandibular Overdenture Users. *Braz Dent J.* 2020 Sep 4;31(4):399-403.
23. Schimmel M, Christou P, Herrmann F, Müller F. A two-colour chewing gum test for masticatory efficiency: development of different assessment methods. *J Oral Rehabil.* 2007 Sep;34(9):671-8.
24. Soni A. Use of loose fitting copper bands over extremely mobile teeth while making impressions for immediate dentures. *J Prosthet Dent.* 1999 May;81(5):638-9.
25. Im J, Cha JY, Lee KJ, Yu HS, Hwang CJ. Comparison of virtual and manual tooth setups with digital and plaster models in extraction cases. *Am J Orthod Dentofacial Orthop.* 2014 Apr;145(4):434-42.
26. Fontijn-Tekamp FA, Slagter AP, Van Der Bilt A, Van 't Hof MA, Witter DJ, Kalk W, Jansen JA. Biting and chewing in overdentures, full dentures, and natural dentitions. *J Dent Res.* 2000 Jul;79(7):1519-24.
27. Bakke M, Holm B, Gotfredsen K. Masticatory function and patient satisfaction with implant-supported mandibular overdentures: a prospective 5-year study. *Int J Prosthodont.* 2002 Nov-Dec;15(6):575-81.
28. Boven GC, Raghoobar GM, Vissink A, Meijer HJ. Improving masticatory performance, bite force, nutritional state and patient's satisfaction with implant overdentures: a systematic review of the literature. *J Oral Rehabil.* 2015 Mar;42(3):220-33.
29. Bennadi D, Reddy CV. Oral health related quality of life. *J Int Soc Prev Community Dent.* 2013 Jan;3(1):1-6.