Mandibular retromolar canal: the ultimate CBCT detection procedure

Abstract

Aim
This study investigates the retromolar canal, an important anatomical variant of the mandibular canal, aiming to provide clinicians with an effective method for its assessment and management. It focuses on a pre-operative identification protocol using Cone Beam Computed Tomography (CBCT) and presents its prevalence in a sample of 200 Caucasian subjects.

Materials and methods
Images from second-level CBCT (NewTom®, Verona, Italy) radiographic examinations were analyzed at the Department of Dentistry, IRCCS San Raffaele Hospital. The study included Caucasian subjects over 18 years old without mandibular bone lesions or prior surgeries in the jaw angle area. One operator analyzed the images using RealGuide® software (3DIEMME®, Cantù, Italy). A narrative review on the retromolar canal was conducted using the PubMed search engine, covering a 10-year period (2013-2023).

Results
Statistical analysis of 200 CBCT scans showed the retromolar canal bilaterally in 62 subjects (31%), unilaterally in 80 subjects (40%), and absent in 58 subjects (29%). The overall prevalence was 71%. Inferential statistical methods were used for analysis.

Conclusion
The study highlights the significance of pre-operative identification of the retromolar canal to reduce surgical complications and invasiveness, thereby enhancing the safety and success of oral surgical procedures.

Authors

Michele Manacorda[1*]
Alberto Borsi[1]
Claudia Caravetta[2]
Francesca Mottola[2]
Federico Raimondi Lucchetti[3]
Raffaele Vinci[3]

1
DDS, Dental School, Vita-Salute San Raffaele University, Milan, Italy and Department of Dentistry, IRCCS San Raffaele Hospital, Milan, Italy

2
DDS, MSC, Dental School, Vita-Salute San Raffaele University, Milan, Italy and Department 10 of Dentistry, IRCCS San Raffaele Hospital, Milan, Italy

3
MD MFS Dental School, Vita-Salute San Raffaele University, Milan, Italy and Department of Dentistry, IRCCS San Raffaele Hospital, Milan, Italy

* Corresponding Author

Keywords

Retromolar canal, Cone beam computed tomography (CBCT), Bifid mandibular canal, Retromolar foramen, Pre-operative identification.

DOI

10.23805/JO.2026.676

INTRODUCTION

The retromolar canal is a distinctive anatomical structure found within the mandible, recognized as an accessory canal branching from the inferior alveolar nerve trunk. Located in the retromolar region, it is categorized as one of the bifid variants of the mandibular canal, specifically classified as type 1 bifidity (1,2). This structure results from the incomplete fusion of nerve trunks during developmental stages (3). Originating from the mandibular canal, the retromolar canal branches posteriorly to the last molar, progressing antero-superiorly through the bone, and ultimately terminating at the retromolar foramen in the fossa of the retromolar trigone (4). Understanding its formation necessitates an examination of embryological development. Research has demonstrated that during prenatal growth, the inferior alveolar nerve develops through three distinct nerve pathways, each within its own canal (5,6). According to the theory proposed by Lomeli et al., the rapid growth and remodeling of the mandibular branch region during prenatal stages lead to the gradual fusion of these canal inputs into a single mandibular canal by birth. Incomplete fusion of these prenatal canals results in the formation of the retromolar canal (7).
The morphology and trajectory of the retromolar canal have been extensively analyzed by various authors. Von Arx, in 2017, classified its course into four distinct patterns: vertical, curved, horizontal, and aberrant (8). The literature consistently indicates that the canal contains a vasculo-nervous bundle, stemming from the inferior alveolar nerve's branching (9,10). Additionally, some studies suggest that aberrant branches of the buccal nerve, which penetrate the buccinator muscle, may also be present within the retromolar canal (11,12). The vasculo-nervous bundle is crucial for providing accessory innervation to the mandibular molars and the mucosa of the retromolar area (13).
Studies have reported wide variability in the prevalence of the retromolar canal, with rates ranging from 5% to 75% (14). This variability can be attributed to multiple factors, including ethnic differences, environmental and genetic influences, study designs, sample types, and sizes. Accurate pre-operative identification of the retromolar canal using radiographic imaging, particularly Cone Beam Computed Tomography (CBCT), is increasingly important in clinical practice. Proper identification helps prevent potential intra-operative and post-operative complications associated with this anatomical structure.
The objective of this study is to establish a protocol for clinicians to effectively identify the retromolar canal using CBCT radiographic examinations. This protocol aims to enhance surgical outcomes and reduce complications related to the mismanagement of this anatomical variant. By utilizing advanced imaging techniques and meticulous mapping processes, clinicians can ensure that they have a comprehensive understanding of the patient's unique anatomy. This understanding is crucial for minimizing surgical risks, improving patient outcomes, and enhancing overall treatment efficacy.

MATERIALS AND METHODS

Images obtained through second-level Cone Beam Computed Tomography (CBCT) radiographic examinations, conducted at the Department of Dentistry, IRCCS San Raffaele Hospital, were meticulously selected for this study. The inclusion criteria for this analysis were: Caucasian subjects aged 18 years or older, irrespective of gender, who had no mandibular bone lesions or history of mandibular body or angle surgery.
The images were acquired using the VGI evo NewTom® CBCT machine (Verona, Italy), set with a 10x10 cm field of view (FOV) and voxel size less than 100 microns, ensuring high-resolution imaging. The acquired images were then reconstructed in axial, coronal, and sagittal projections using 3Diagnosys® 6.2 software by 3DIEMME® (Cantù, Italy) (17).
A single experienced operator in digital diagnostics performed the image evaluations to maintain consistency and accuracy. Informed consent was obtained from all patients for their inclusion in the study analysis.
The criteria for identifying the presence of an accessory canal were clearly defined. The identification relied on detecting a break in the upper bony cortical of the mandibular canal within the retromolar area, which indicates the bifurcation of the main bundle. Additionally, the presence of a radiolucent band crossing the bony structure in an antero-superior direction and terminating on the cranial surface of the retromolar trigone was crucial. This radiolucent band culminates in a circumscribed radiolucent area, indicating the location of the retromolar foramen (Figure 1).

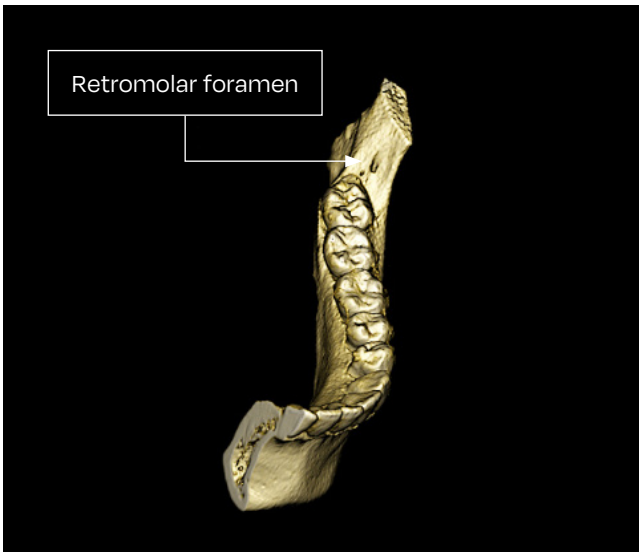

Fig. 1 Retromolar foramen in a 3D volume emi-mandibular reconstruction.

The protocol established in this study aims to standardize the detection and interpretation of this anatomical variant, thereby reducing potential complications during surgical procedures involving the mandible.
The significance of this research lies in its potential to inform clinical practices and improve patient care by providing a detailed and methodical approach to identifying the retromolar canal through advanced imaging techniques. By employing high-resolution CBCT imaging and rigorous evaluation criteria, this study contributes to a deeper understanding of mandibular anatomy and its variations, which is essential for optimizing surgical planning and execution.

Retromolar canal search protocol

STEP 1: Panorex Creation

To create a Panorex, begin by manually drawing a line along the mandibular arch on the axial section of the CBCT. The line should pass through the middle of the canine root and be parallel to the occlusal plane (Figure 2). This process requires careful attention to anatomical landmarks to ensure accuracy and relevance to the patient's specific dental structure.

- Start Point: Begin the line distal to the posterior margin of the mandibular branch. This starting point ensures that the entire mandibular structure is encompassed, providing a comprehensive view for subsequent steps.
- Path Through Lingual Concavity: The line should pass through the lingual concavity of the mandibular branch. This part of the path is crucial as it navigates the inner curvature of the mandible, reflecting the natural contour of the bone.
- Pass Through Retromolar Trigone: Extend the line through the distal portion of the retromolar trigone. The retromolar trigone is a significant anatomical landmark because it is often where the retromolar canal originates. Accurate tracing here ensures that any variations in this area are captured.
- Intersecting Root Sections: As the line continues, it should intersect the root sections, carrying vestibularly into the premolar area. This intersection is important for visualizing how the canal navigates around the roots of the teeth, which can influence surgical planning and outcomes.
- Completing the Curve: Finally, complete the curve by manually drawing the rest of the mandibular arch. This step allows for adjustments based on individual anatomical variations, ensuring a tailored and precise representation of the mandibular arch.

This curve defines an "ortoradial" section of the mandibular arch, known as Panorex. The Panorex provides a detailed and panoramic view of the mandible, essential for diagnosing and planning treatment for various dental and maxillofacial conditions.

STEP 2: Modification of the Vestibulo-Lingual Thickness of the Panorex

The vestibulo-lingual thickness of the ortoradial section significantly affects the image obtained. The thickness must be adjusted to provide a clear and detailed view of the mandibular canal.

- Thickness and Image Resemblance: The thicker the section, the more the image resembles traditional orthopantomography (OPT). However, if the section is too thick, important details may be obscured. Conversely, a thinner section provides greater detail but

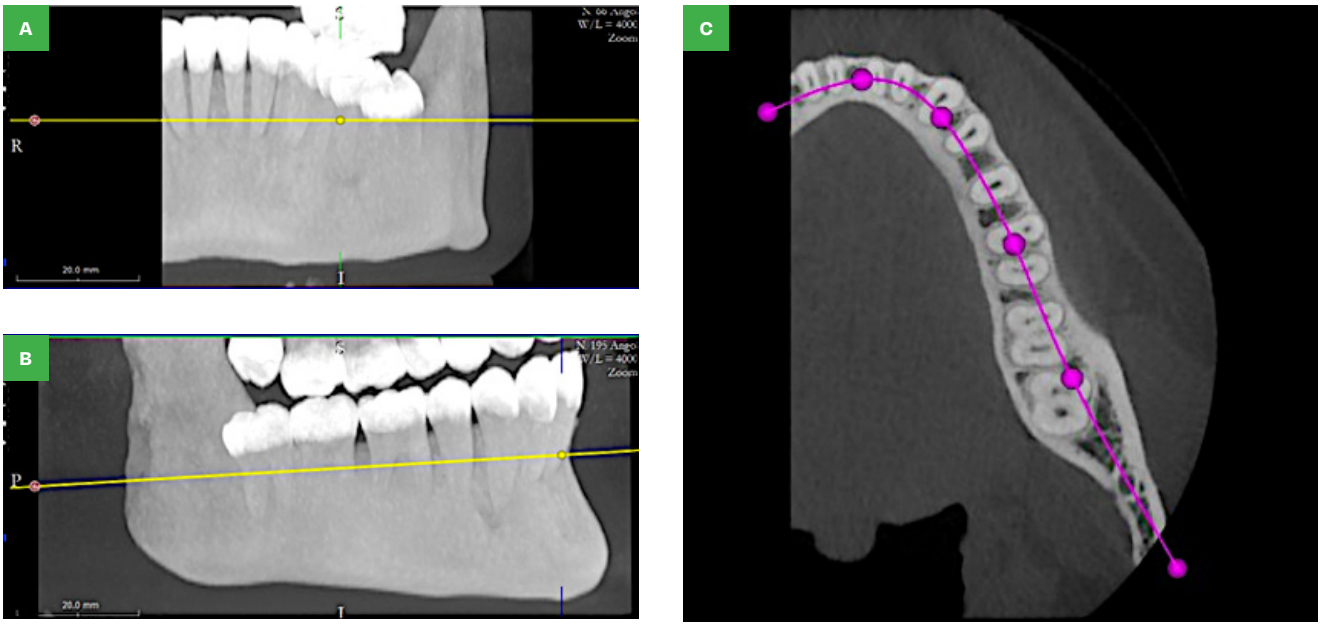

Fig. 2 (A, B) positioning of the line at the middle of the canine root and parallel to the occlusal plane: 3D reconstruction view **(C)** selected point for the drawn line on the axial view.

may require more precise adjustments to capture the entire mandibular canal.
- Adjusting Thickness for Clarity: If sufficient information about the canal path is not obtained, modify the thickness to increase the definition of the inferior alveolar nerve (IAN) path. This involves progressively reducing the thickness and marking points with greater precision until the entire IAN is sharply framed on the Panorex image.
- Optimal Thickness Range: According to our study, appropriate thicknesses in multi-planar reconstruction (MPR) mode range from 1 to 3mm. This range balances detail and comprehensiveness, ensuring that the mandibular canal and its variations are clearly visible.

This step is crucial for enhancing the visibility of the IAN and retromolar canal, facilitating accurate diagnosis and surgical planning.

STEP 3: Search for the Retromolar Canal

Once the entire mandibular path of the IAN is visualized on the Panorex, the next step is to identify the retromolar canal.
- Visualizing the IAN Path: Ensure that the entire path of the IAN is clearly visible on the Panorex. This comprehensive view is necessary to identify any collateral branches accurately.
- Identifying the Retromolar Canal: Look for a collateral branch of the mandibular canal that departs in a cranial (or antero-superior) direction from the main mandibular canal at the level of the retromolar trigone (Figure 3). This branch is the retromolar canal, which often appears as a distinct offshoot from the main canal.
- Importance of Accurate Identification: Identifying the retromolar canal accurately is critical for planning surgical interventions. The presence of this canal can influence decisions regarding the extent of bone removal, the approach to anesthesia, and the management of potential complications.

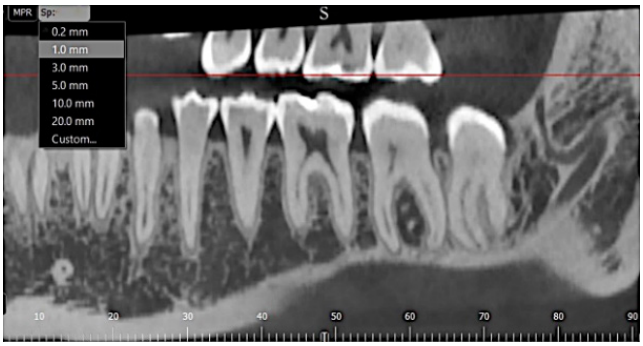

Fig. 3 Panorex of a left mandibular CBCT reconstruction showing a large retromolar canal growing from the mandibular canal.

This step ensures that the retromolar canal is correctly identified, which is essential for the subsequent steps in the identification and mapping process.

STEP 4: Highlighting the Path of the Retromolar Canal

Once the retromolar canal is identified, the next step is to highlight its path using imaging software.
- Marking the Bifurcation: Mark the retromolar canal at the level of its bifurcation from the IAN on the Panorex. This marking serves as a reference point for tracing the canal's path through the mandibular bone.
- Changing Views for Complete Visualization: Change the view to radial sections to visualize the path of the retromolar canal in three planes of space (Figure 4). This multi-dimensional view provides a comprehensive understanding of the canal's trajectory, ensuring that no details are overlooked.
- Importance of 3D Visualization: Highlighting the retromolar canal in three dimensions is essential

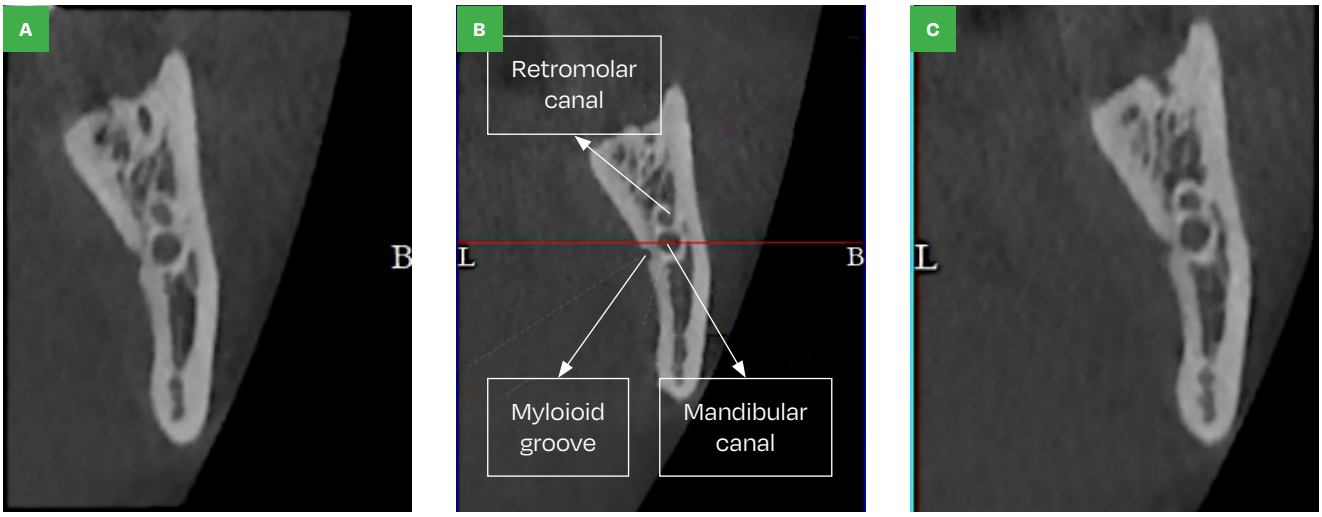

Fig. 4A-4C Visualization of the retromolar canal on the cross-section of the CBCT.

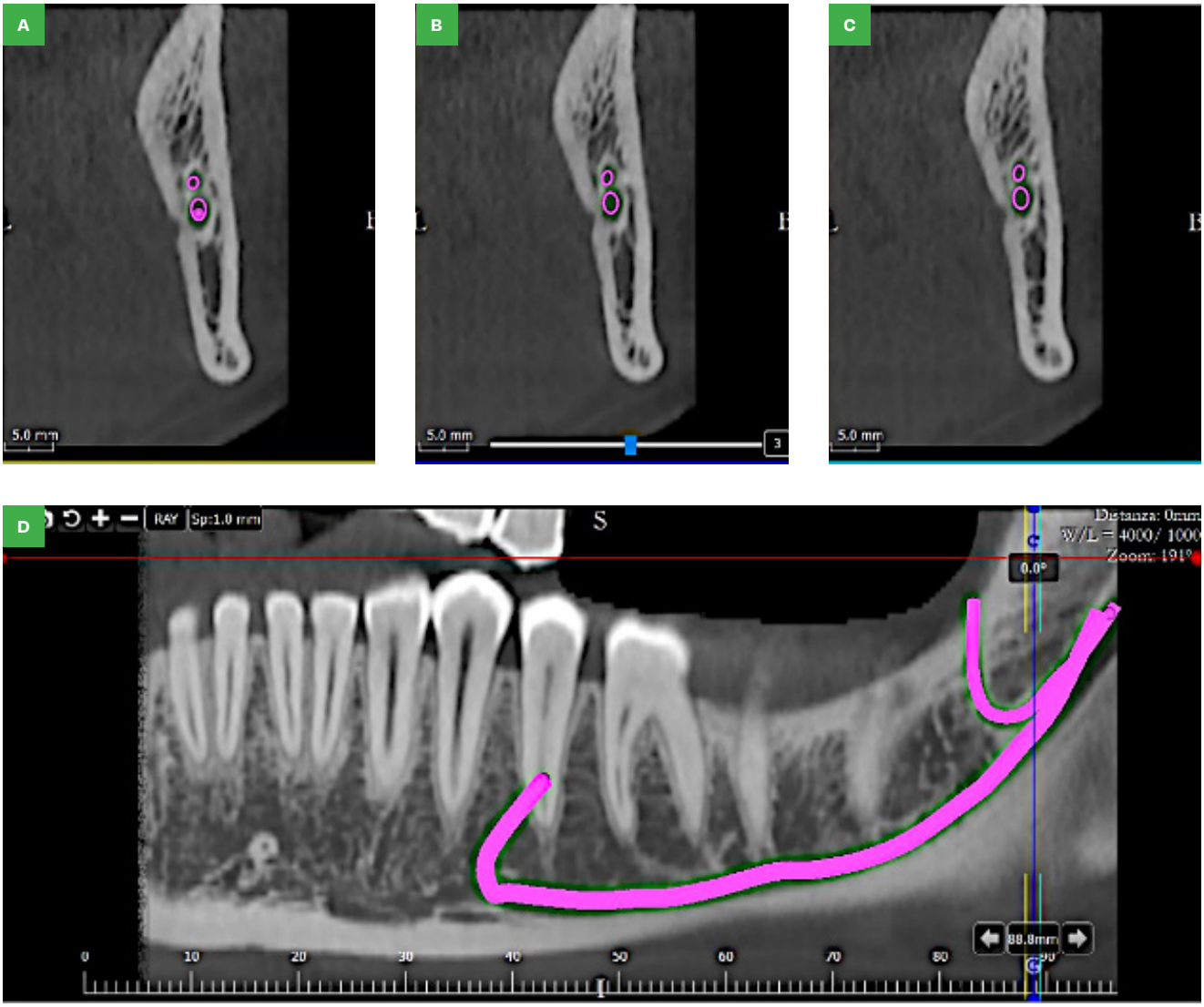

Fig. 5A-5D Drawn path of the retromolar canal and IAN.

for accurate mapping. This step allows clinicians to appreciate the canal's course relative to surrounding anatomical structures, which is vital for surgical planning and risk assessment.

By highlighting the retromolar canal, clinicians can gain a thorough understanding of its path, facilitating precise surgical interventions.

STEP 5: Drawing the Path of the Retromolar Canal

The final step involves drawing the path of the retromolar canal using the imaging software's "add nerve" function.

- Selecting Diameter: Select a diameter of about 1-1.5mm, which corresponds to the typical size of the retromolar canal. This selection ensures that the drawn path accurately reflects the canal's actual dimensions.
- Drawing the Path: Draw the path of the retromolar canal on the Panorex. This step involves tracing the canal from its bifurcation point through its entire course within the mandibular bone.
- Verification of Position: Verify the bucco-lingual position of the drawn path on the cross-sections. This verification ensures that the drawn path aligns with the actual anatomical position of the retromolar canal, providing a reliable reference for surgical planning (Figure 5).
- Importance of Accurate Drawing: Accurately drawing the retromolar canal's path is critical for understanding its relationship with surrounding structures. This information can help clinicians anticipate potential complications and modify their surgical approach accordingly.

By drawing and verifying the path of the retromolar canal, clinicians can ensure that they have a precise map of this anatomical structure, aiding in the planning and execution of surgical procedures.

Analysis and Significance of Each Step

Step 1: Panorex Creation

Creating a Panorex involves careful manual tracing of the mandibular arch on the axial section of the CBCT. This process starts distal to the posterior margin of the mandibular branch and proceeds through various critical anatomical landmarks, including the lingual concavity, the retromolar trigone, and the premolar area. Each point on the path is chosen to ensure a comprehensive and accurate representation of the mandibular arch. The Panorex provides a panoramic view of the mandible, essential for diagnosing various dental and maxillofacial conditions. The manual nature of this step allows for adjustments based on individual anatomical variations, ensuring a tailored and precise representation.

Step 2: Modification of the Vestibulo-Lingual Thickness

The thickness of the ortoradial section significantly impacts the clarity and detail of the Panorex image. A thicker section may resemble traditional OPT images, but it might obscure finer details necessary for visualizing the IAN path. Adjusting the thickness allows for fine-tuning the image quality, ensuring that the IAN is clearly visible. The optimal thickness range of 1-3mm in MPR mode balances detail and comprehensiveness, providing a clear view of the mandibular canal and its variations. This step is crucial for enhancing the visibility of the IAN and retromolar canal, facilitating accurate diagnosis and surgical planning.

Step 3: Search for the Retromolar Canal

Visualizing the entire mandibular path of the IAN on the Panorex is a prerequisite for identifying the retromolar canal. The retromolar canal typically departs from the mandibular canal in a cranial or antero-superior direction at the level of the retromolar trigone. This step involves careful examination of the Panorex image to identify this collateral branch. Accurate identification of the retromolar canal is essential for planning surgical interventions, as its presence can influence decisions regarding bone removal, anesthesia, and management of potential complications.

Step 4: Highlighting the Path of the Retromolar Canal

Highlighting the retromolar canal involves marking its bifurcation from the IAN on the Panorex and changing the view to radial sections for complete visualization in three planes of space. This multi-dimensional view is essential for understanding the canal's trajectory relative to surrounding structures. Highlighting the retromolar canal in three dimensions ensures that no details are overlooked, providing a comprehensive understanding of its course. This step is crucial for accurate mapping and surgical planning, as it allows clinicians to appreciate the canal's path and anticipate potential complications.

Step 5: Drawing the Path of the Retromolar Canal

The final step involves using the "add nerve" function in the imaging software to draw the path of the retromolar canal. Selecting a diameter of 1-1.5mm ensures that the drawn path accurately reflects the canal's actual dimensions. The path is drawn on the Panorex and verified for accuracy by examining its bucco-lingual position on cross-sections. Accurately drawing and verifying the path of the retromolar canal provides a reliable reference for surgical planning. This information helps clinicians anticipate potential complications and modify their surgical approach accordingly. This final step ensures that clinicians have a precise map of the retromolar canal, which is crucial for planning and executing surgical procedures with minimal risk of complications.

Clinical Relevance of Each Step

Step 1: Panorex Creation

The creation of the Panorex is foundational for visualizing the mandibular arch in a comprehensive manner. This panoramic view is essential not only for diagnosing dental pathologies but also for planning surgical interventions. By meticulously tracing the mandibular arch, clinicians can ensure that they capture the entire anatomical landscape of the mandible, including critical areas that might be impacted during surgery. The Panorex serves as a baseline image that guides all subsequent steps in the identification and mapping of the retromolar canal.

Step 2: Modification of the Vestibulo-Lingual Thickness

Adjusting the vestibulo-lingual thickness is crucial for achieving the right balance between image clarity and comprehensiveness. A well-modified thickness ensures that the image provides enough detail to identify the IAN path clearly without losing the broader context of the mandibular structure. This step is particularly important for identifying subtle anatomical variations that could affect surgical outcomes. For instance, a precise thickness adjustment might reveal narrow segments of the canal or small bifurcations that could be missed in thicker, less detailed images.

Step 3: Search for the Retromolar Canal

The identification of the retromolar canal is a critical step in surgical planning. Knowing the exact location and course of this canal can prevent potential complications during surgery. For example, during third molar extractions, the retromolar canal's presence might necessitate changes in the surgical approach to avoid nerve damage. Accurate identification also helps in

planning for adequate anesthesia and managing intraoperative bleeding. This step ensures that surgeons are fully informed about the anatomical landscape they will be operating in.

Step 4: Highlighting the Path of the Retromolar Canal
Highlighting the retromolar canal in three dimensions provides a comprehensive understanding of its trajectory. This multi-plane visualization is essential for appreciating the canal's relationship with other anatomical structures, such as the roots of the teeth and the mandibular cortex. This understanding helps in planning the surgical approach, deciding on the extent of bone removal, and predicting potential complications. Highlighting the canal also aids in educating patients about their unique anatomy and the implications for their treatment.

Step 5: Drawing the Path of the Retromolar Canal
Drawing the path of the retromolar canal with the "add nerve" function and verifying it on cross-sections ensures that the canal's course is accurately mapped. This step provides a visual and spatial reference that can be used during surgery to guide the surgeon's actions. For instance, the drawn path can help in determining the safest points for incisions or bone removal. It also serves as a critical reference for avoiding the canal during implant placements or other invasive procedures. Accurate mapping minimizes the risk of nerve damage and postoperative complications such as numbness or pain.

Statistical Analysis

The data were analyzed using R software, which is released under the Free Software Foundation's GNU General Public License. The analysis employed descriptive statistical methods to provide a comprehensive overview of the data set. Specifically, the mean, standard deviation, and frequency were calculated to summarize the central tendency and variability within the data.
To investigate potential associations within the data, a chi-square test was conducted. This statistical test was used to determine if there was a significant association between gender (male-female) and the presence or absence of the retromolar canal. The retromolar canal was categorized as absent, monolateral (present on one side), or bilateral (present on both sides). The chi-square test also assessed the significance of the prevalence of the retromolar canal's presence, providing insights into whether its occurrence was statistically significant across the sampled population.
The combination of descriptive statistics and chi-square analysis allowed for a thorough examination of the data, highlighting any notable patterns or associations that could inform further research or clinical practice.

RESULTS

The search conducted using the selected parameters enabled the analysis of 200 consecutive CBCT images from patients of the Caucasian population. The age range of the study subjects was between 19 and 92 years, with an arithmetic mean age of 56 years (standard deviation: ±18.3 years). This wide age range ensures a comprehensive understanding of the retromolar canal's presence across different age groups within the Caucasian demographic.
The statistical analysis of the collected data revealed interesting insights regarding the presence of the retromolar canal. It was found that the retromolar canal was present bilaterally in 62 subjects, which corresponds to 31% of the study population. In 80 subjects, or 40% of the population, the retromolar canal was present in only one of the two mandibular branches. This indicates a prevalence of the retromolar canal in 71% of the subjects. Conversely, in 29% of the subjects, the retromolar canal was absent bilaterally. This high prevalence rate underscores the importance of considering the retromolar canal in clinical assessments and surgical planning.
To further investigate the distribution of the retromolar canal among the study population, a chi-square analysis was conducted. The analysis compared the distribution of the retromolar canal as absent, monolateral, or bilateral. The results showed no significant differences in the distribution of these variables, with a chi-square value of 3.87 and a p-value of 0.15. This suggests that the presence or absence of the retromolar canal, whether bilaterally or monolaterally, does not significantly vary within this population sample (Figure 6). This finding

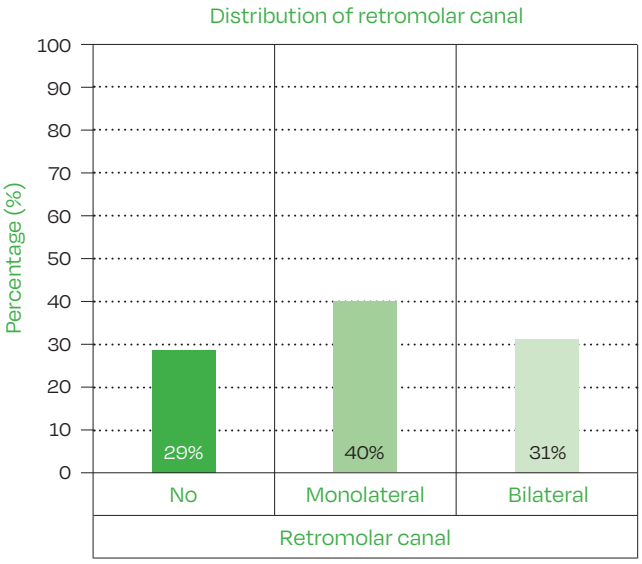

Fig. 6 Prevalence and distribution of the retromolar canal in the analyzed sample.

is crucial as it indicates a consistent prevalence of the retromolar canal, making it a reliable anatomical variant to consider in clinical practice.
The sample analyzed comprised 83 males, representing 41.5% of the population, and 117 females, making up the remaining 58.5%. This gender distribution allows for a detailed analysis of any potential sex-based differences in the prevalence of the retromolar canal. Among the female subjects, the retromolar canal was absent in 33% of cases. Conversely, the canal was present in 67% of the females, with 35% showing a unilateral presence and 32% displaying a bilateral presence. This significant presence in females suggests that the retromolar canal is a common anatomical variant that should be considered during dental and surgical procedures involving female patients.
In the male subjects, the retromolar canal was absent in 23% of cases. For the remaining 77% of the male subjects, the canal was present, with 47% showing a unilateral presence and 30% showing a bilateral presence (Figure 7). This higher prevalence in males, particularly the unilateral presence, may have implications for surgical approaches and anesthesia management in male patients.
The statistical analysis indicated that the prevalence of the retromolar canal did not differ significantly between sexes. A 2 x 3 chi-square test was conducted to examine the association between gender (male vs. female) and the presence of the retromolar canal (absent vs. monolateral vs. bilateral). The results revealed no significant association between these variables, with a chi-square value of 3.59 and a p-value of 0.17. This suggests that the distribution of the retromolar canal, whether absent, monolateral, or bilateral, does not significantly vary between males and females. This lack of significant gender difference reinforces the idea that the retromolar canal is a common anatomical variant that can be expected in both sexes.
The comprehensive analysis of the CBCT images highlights the importance of considering the retromolar canal in dental and surgical practices. The high prevalence of this canal, coupled with the lack of significant gender differences, suggests that clinicians should routinely check for its presence during preoperative assessments. Accurate identification of the retromolar canal can help prevent intra-operative and post-operative complications, such as nerve injury or excessive bleeding, thereby improving patient outcomes.
Future research should focus on exploring the implications of the retromolar canal in various ethnic groups and its impact on different dental and surgical procedures. Additionally, developing standardized protocols for the identification and management of the retromolar canal can further enhance clinical practice, ensuring that all patients receive the highest standard of care.

DISCUSSION

The ramifications of the mandibular canal, particularly the retromolar canal, have been extensively studied in the literature. Initially considered an anatomical abnormality, the retromolar canal is now recognized as a variant of normal mandibular canal anatomy, as demonstrated by numerous studies examining its prevalence across different populations (2).
Our findings align with previous research, indicating a significant prevalence of the retromolar canal. This study reported a retromolar canal prevalence of 71%, with 31% of subjects displaying bilateral canals and 40% showing unilateral canals. These results underscore the importance of recognizing this anatomical variant in clinical practice.

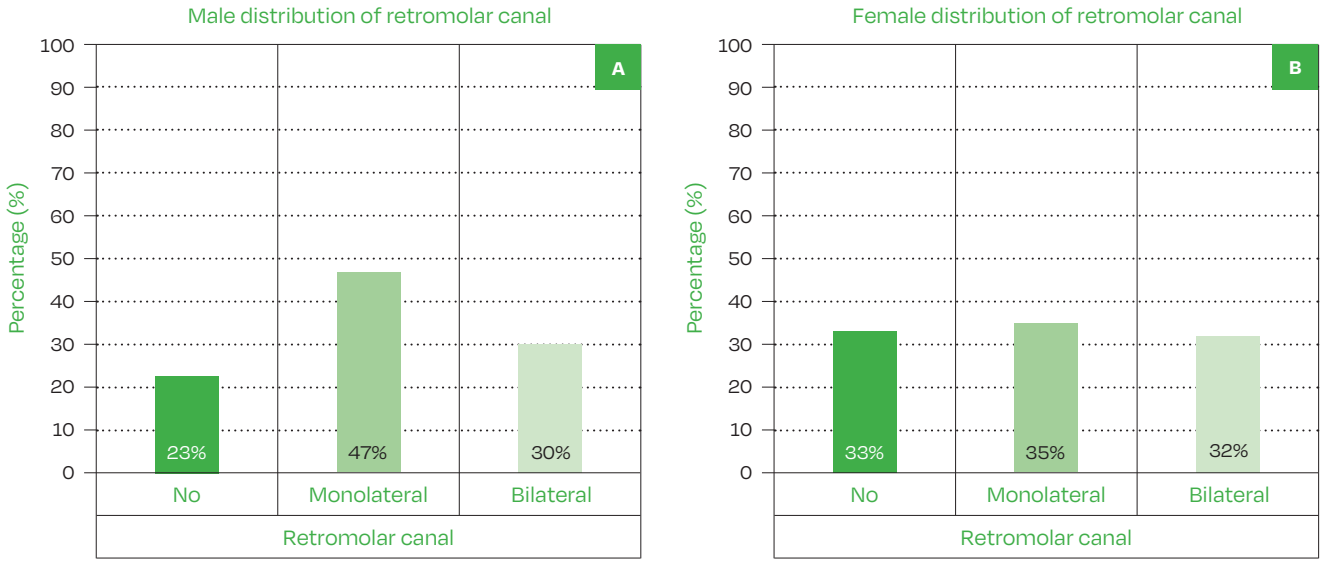

Fig. 7A, 7B Prevalence of the retromolar canal according to sample gender.

One of the critical observations in the literature is the heterogeneity in methodologies, ranging from cadaver studies to radiographic analyses, and variations in sample types and sizes (18). Such diversity contributes to the wide range of reported prevalence rates, as highlighted by Aung et al.'s meta-analysis (1). This meta-analysis noted prevalence rates from 3.2% to 72% in cadaver studies, 3.06% to 8.8% in orthopantomography (OPT) studies, and 5.4% to 75.4% in cone beam CT (CBCT) studies (16). The inconsistencies in these findings emphasize the need for standardized protocols in future research to achieve more consistent and reliable data.

Technological advancements have significantly enhanced our ability to identify the retromolar canal. Modern imaging tools like CBCT offer superior resolution and accuracy compared to older methods like OPT. Our study supports this, indicating that CBCT, with a voxel size of less than 100 µm, provides the most reliable identification of the retromolar canal. This aligns with the literature suggesting that smaller voxel sizes enhance the resolution of CBCT images, making it easier to detect fine anatomical structures (1). The precision offered by CBCT is crucial for accurate preoperative assessment and planning, particularly in complex cases where the anatomical details can influence surgical outcomes.

The discrepancies in prevalence rates can be attributed to several factors, including ethnic differences, environmental and genetic influences, sample size, identification criteria, and imaging techniques. For instance, OPT often produces artifacts due to overlapping structures, leading to potential underestimation of the retromolar canal's presence (19–22). In contrast, CBCT allows for a more detailed and accurate assessment, as demonstrated in studies comparing these two modalities (24). These findings highlight the necessity of choosing appropriate imaging techniques based on the specific diagnostic needs and the anatomical area of interest.

The clinical implications of the retromolar canal are profound, particularly in oral surgeries involving the retromolar area. The presence of neurovascular structures within the canal, as confirmed by histological studies (25,26), can complicate procedures such as third molar extractions, bone grafts from the mandibular branch, and excisions of osteolytic lesions. These structures provide additional blood and nerve supply to critical areas, potentially increasing pain and anesthesia challenges during surgery (27,28). Moreover, inadvertent injury to these structures can result in post-operative complications such as increased pain, altered mucosal sensitivity, and significant bleeding (29–31). The anatomical knowledge of the retromolar canal is therefore essential for surgeons to minimize intraoperative risks and optimize patient care.

CONCLUSION

Within the limitations of the present study, the results highlight the crucial importance of pre-operative identification of the retromolar canal within the mandible. The high prevalence of the retromolar canal, as confirmed by our results, emphasizes the necessity of incorporating this anatomical feature into routine clinical assessments. The potential surgical complications associated with the presence of the retromolar canal, such as nerve damage and excessive bleeding, underscore the need for accurate assessment and planning.

The study demonstrated that the retromolar canal was present in 71% of the subjects, with 31% showing bilateral presence and 40% showing unilateral presence. This significant prevalence rate makes it imperative for clinicians to identify this canal before performing any surgical procedures in the mandibular region. Accurate pre-operative identification can prevent unforeseen complications and enhance the overall safety of surgical interventions.

To achieve precise identification of the retromolar canal, second-level radiographic examinations with specific settings are recommended. CBCT provides high-resolution, three-dimensional images that allow for detailed visualization of the mandibular anatomy, including the retromolar canal. This advanced imaging technique surpasses traditional radiographic methods in accuracy and reliability, making it the preferred choice for pre-operative assessments.

The protocol proposed in this study offers a systematic approach for clinicians to identify the retromolar canal using CBCT. This protocol involves several key steps: creating a Panorex by manually drawing the mandibular arch on the axial section of the CBCT, modifying the vestibulo-lingual thickness to enhance image clarity, searching for the retromolar canal by visualizing the entire IAN path, highlighting the canal's path using radial sections, and finally, drawing the path of the retromolar canal using the "add nerve" function in the imaging software. Each step is designed to provide a comprehensive understanding of the canal's trajectory and its relationship with surrounding anatomical structures.

Implementing this protocol can significantly reduce intra-operative and post-operative complications. For instance, during third molar extractions, knowing the exact location of the retromolar canal can guide the surgeon in avoiding nerve damage and minimizing bleeding. Similarly, in procedures involving mandibular osteotomies or implant placements, understanding the canal's path can prevent accidental injury to the vasculo-nervous bundle contained within the canal.

Early identification of the retromolar canal also allows for better patient education and informed consent. Patients can be made aware of the potential risks associated with their specific anatomy and the measures that will be taken to mitigate these risks. This transparency can enhance patient trust and satisfaction with the surgical process.

Furthermore, the study's findings suggest that the prevalence of the retromolar canal does not significantly differ between males and females. This consistency across genders reinforces the need for universal screening for the retromolar canal in all patients undergoing mandibular surgery.

Future research should aim to explore the prevalence of the retromolar canal in diverse ethnic groups and its impact on different dental and surgical procedures. Additionally, developing standardized protocols for the identification and management of the retromolar canal can further enhance clinical practice, ensuring that all patients receive the highest standard of care.

In summary, the high prevalence of the retromolar canal and the associated surgical risks underscore the importance of accurate pre-operative identification using CBCT. The proposed protocol provides a reliable means for clinicians to visualize and map the retromolar canal, thereby reducing surgical complications and improving patient outcomes. By integrating this protocol into routine clinical practice, surgeons can enhance the safety and success of oral surgical procedures, ultimately leading to better patient care.

Further clinical study could be necessary to confirm the obtained results.

REFERENCES

1 Aung NM, Myint KK. Bifid Mandibular Canal: A Proportional Meta-Analysis of Computed Tomography Studies. Int J Dent 2023;2023. https://doi.org/10.1155/2023/9939076.
2 Motamedi MHK, J. Gharedaghi, S. Mehralizadeh, F. Navi, A. Badkoobeh NV, Azizi T. Anthropomorphic assessment of the retromolar foramen and retromolar nerve: anomaly or variation of normal anatomy? 2016.
3 Langlais RP, Broadus R, Glass BJ. Bifid mandibular canals in panoramic radiographs. J Am Dent Assoc 1985;110:923–6. https://doi.org/10.14219/jada.archive.1985.0033.
4 de Gringo CPO, de Gittins EVCD, Rubira CMF. Prevalence of retromolar canal and its association with mandibular molars: study in CBCT. Surg Radiol Anat 2021;43:1785–91. https://doi.org/10.1007/s00276-021-02787-6.
5 Ngeow WC, Chai WL. The clinical significance of the retromolar canal and foramen in dentistry. Clin Anat 2021;34:512–21. https://doi.org/10.1002/ca.23577.
6 Serres Renaud. Essai sur l'anatomie et la physiologie des dents. 1817.
7 Haas LF, Dutra K, Porporatti AL, Mezzomo LA, De Luca Canto G, Flores-Mir C, et al. Anatomical variations of mandibular canal detected by panoramic radiography and CT: A systematic review and meta-analysis. Dentomaxillofacial Radiol 2015;45:1–12. https://doi.org/10.1259/dmfr.20150310.
8 Chávez-Lomelí ME, Mansilla Lory J, Pompa JA, Kjær I. The human mandibular canal arises from three separate canals innervating different tooth groups. J Dent Res 1996;75:1540–4. https://doi.org/10.1177/00220345960750080401.
9 Von Arx T, Hänni A, Sendi P, Buser D, Bornstein MM. Radiographic study of the mandibular retromolar canal: An anatomic structure with clinical importance. J Endod 2011;37:1630–5. https://doi.org/10.1016/j.joen.2011.09.007.
10 Ossenberg NS. Retromolar foramen of the human mandible. Am J Phys Anthropol 1987;73:119–28. https://doi.org/10.1002/ajpa.1330730112.
11 Patil S, Matsuda Y, Okano T. Accessory mandibular foramina: A CT study of 300 cases. Surg Radiol Anat 2013;35:323–30. https://doi.org/10.1007/s00276-012-1044-6.
12 Von Arx TLS. Retromolar canal. In: Springer, editor. Clin. ora Anat., n.d., p. 369–83.
13 Fukami K, Shiozaki K, Mishima A, Kuribayashi A, Hamada Y, Kobayashi K. Bifid mandibular canal: Confirmation of limited cone beam CT findings by gross anatomical and histological investigations. Dentomaxillofacial Radiol 2012;41:460–5. https://doi.org/10.1259/dmfr/60245722.
14 Kim HJ, Kang H, Seo YS, Kim DK, Yu SK. Anatomic evaluation of the retromolar canal by histologic and radiologic analyses. Arch Oral Biol 2017;81:192–7. https://doi.org/10.1016/j.archoralbio.2017.05.012.
15 Jablonski NG, Cheng CM, Cheng LC, Cheung HM. Unusual origins of the buccal and mylohyoid nerves. Oral Surgery, Oral Med Oral Pathol 1985;60:487–8. https://doi.org/10.1016/0030-4220(85)90235-X.
16 Setu P. Shah DM. Mandibular Retromolar Foramen and Canal - A Systematic Review and Meta-Analysis. Ann Maxillofac Surg 2020;10:444–9.
17 Merlone A, Tetè G, Cantile N, . Manacorda M, Cattoni F. Minimally invasive digital implant-prosthetic procedure in "all on 4" rehabilitation in patients with special needs: a three-year follow-up. J Biol Regul Homeost Agents 2021;35:71–85.
18 Shan S, Zhong S, Li J, Wang T. Systematic review and meta-analysis of mandibular canal variations on cone beam computed tomography. Oral Radiol 2022:5–11. https://doi.org/10.1007/s11282-022-00610-5.
19 Truong MK, He P, Adeeb N, Oskouian RJ, Tubbs RS, Iwanaga J. Clinical Anatomy and Significance of the Retromolar Foramina and Their Canals: A Literature Review. Cureus 2017;9. https://doi.org/10.7759/cureus.1781.
20 Salvador, J.; Medeiros, P; Ferreira Junior, O; Capelozza A. Anatomia radiográfi ca do canal mandibular e suas variações em radiografi as panorâmicas. Innov Implant J, Biomater Esthet, São Paulo, v 5, n 2, p 19-24, Maio/Ago 2010 19 2010:19–24.
21 Neves FS, Nascimento MCC, Oliveira ML, Almeida SM, Bóscolo FN. Comparative analysis of mandibular anatomical variations between panoramic radiography and cone beam computed tomography. Oral Maxillofac Surg 2014;18:419–24. https://doi.org/10.1007/s10006-013-0428-z.
22 Naitoh M, Nakahara K, Suenaga Y, Gotoh K, Kondo S, Ariji E. Comparison between cone-beam and multislice computed tomography depicting mandibular neurovascular canal structures. Oral Surgery, Oral Med Oral Pathol Oral Radiol Endodontology 2010;109:e25–31. https://doi.org/10.1016/j.tripleo.2009.08.027.
23 Valenzuela-Fuenzalida JJ, Cariseo C, Gold M, Díaz D, Orellana M, Iwanaga J. Anatomical variations of the mandibular canal and their clinical implications in dental practice: a literature review. Surg Radiol Anat 2021;43:1259–72. https://doi.org/10.1007/s00276-021-02708-7.
24 Okumuş Ö, Dumlu A. Prevalence of bifid mandibular canal according to gender, type and side. J Dent Sci 2019;14:126–33. https://doi.org/10.1016/j.jds.2019.03.009.
25 Bilecenoglu B, Tuncer N. Clinical and Anatomical Study of Retromolar Foramen and Canal. J Oral Maxillofac Surg 2006;64:1493–7. https://doi.org/10.1016/j.joms.2006.05.043.
26 Choi YY, Han SS. Double mandibular foramen leading to the accessory canal on the mandibular ramus. Surg Radiol Anat 2014;36:851–5. https://doi.org/10.1007/s00276-014-1310-x.
27 Grover PS, Lorton L. Bifid mandibular nerve as a possible cause of inadequate anesthesia in the mandible. J Oral Maxillofac Surg 1983;41:177–9. https://doi.org/10.1016/0278-2391(83)90076-9.
28 Moreno Rabie C, Vranckx M, Rusque MI, Deambrosi C, Ockerman A, Politis C, et al. Anatomical relation of third molars and the retromolar canal. Br J Oral Maxillofac Surg 2019;57:765–70. https://doi.org/10.1016/j.bjoms.2019.07.006.
29 Arakeri G, Brennan P, Sagoo M. Neurovascular plexus theory for "escape pain phenomenon" in lower third molar surgery. Plast Aesthetic Res 2015;2:107. https://doi.org/10.4103/2347-9264.157098.
30 Gamieldien MY, Van Schoor A. Retromolar foramen: an anatomical study with clinical considerations. Br J Oral Maxillofac Surg 2016;54:784–7. https://doi.org/10.1016/j.bjoms.2016.05.011.
31 Kikuta S, Iwanaga J, Nakamura K, Hino K, Nakamura M, Kusukawa J. The retromolar canals and foramina: radiographic observation and application to oral surgery. Surg Radiol Anat 2018;40:647–52. https://doi.org/10.1007/s00276-018-2005-5.