

# Soft tissue improvement in immediate dental implant placement by using bone graft around dental implant healing abutments: a novel technique



## Abstract

### Background and Objective

Dental implants have become a standard solution for tooth replacement, offering high success rates. However, improving aesthetic outcomes and patient satisfaction has driven the development of new techniques aimed at enhancing soft tissue stability around implants. This study explores the impact of immediate implant placement combined with bone grafts around the implant and healing caps on soft tissue thickness and height.

### Material and Methods

A prospective clinical study was conducted on ten patients undergoing immediate tooth extraction and implant placement. Eighteen implants were placed, and bone grafts were applied around the implant and healing caps. The study measured gingival thickness and height before extraction and after six months,

using injection needles and transgingival probing methods.

### Results

The study observed significant increases in gingival thickness and height after six months, with a mean gingival height of 3.916 mm and a mean gingival thickness of 4.266 mm, compared to pre-extraction measurements of 1.311 mm and 1.93 mm, respectively. The gingival tissue demonstrated stability and good aesthetic outcomes.

### Conclusion

Immediate implant placement with the use of bone grafts around implants and healing caps significantly enhances soft tissue stability and aesthetics, offering a promising approach for improving long-term implant success and patient satisfaction.

## Authors

**Kocher Mamrash<sup>1</sup>**  
**Shehab Ahmed Hamad<sup>2</sup>**

<sup>1</sup> Oral surgeon (B.D.S., MSc., PhD)  
Kurdistan Higher Council of Medical  
Specialities, Erbil, Iraq

<sup>2</sup> BDS, MSc, MOMSRCPs (Glasg.),  
FIBMS, FICD, FFDRCSI (OSOM),  
FDSRCPs (Glasg.), FDSRCS,  
MFDTRCSED, Professor of  
maxillofacial surgery,  
Kurdistan Higher Council of Medical  
Specialities, Erbil, Iraq

## DOI

10.23805/JO.2026.738

## Keywords

**Bone graft,  
bone substitutes,  
gingival biotype,  
healing abutments,  
immediate placement.**

## INTRODUCTION

In daily practice, implant installation is a standard medical method to restore lost teeth. Even with this medical procedure's well-established high success and survival rates, issues can still arise (1). Alghamdi (2) established the generally accepted standards for evaluating implant success, including the clinical proof that implants have survived and that osseointegration has occurred. Over the last thirty years, various metrics have been used to evaluate the performance of implants, such as survival rates, prosthesis stability over time, radiographic bone loss, and lack of infection in the soft tissues surrounding the implant (3). With the advancement in oral implantology, additional criteria have been introduced to measure success, which aligns with recent developments. These include patient satisfaction, prosthodontic parameters, aesthetics, and natural-looking peri-implant soft tissues. Therefore, assessing the clinical effectiveness of the existing implant-prosthetic techniques is only possible using implant survival rates (4). Instead, there is a need for a clinical outcome reporting on the implant/prosthodontic complex as a single functional unit and not as a composite of its individual components. However, in implant dentistry, osseointegration remains a factor of paramount importance. The current definition of success criteria should be comprehensive and encompass the other aspects.

According to Cosyn et al. (5), modern dentistry highly values aesthetics, emphasizing the need to include additional variables in evaluating implant prostheses' success criteria. The construction of lifelike implant restorations with natural-looking peri-implant soft tissues has taken precedence over implant longevity, highlighting the significance of the patient's satisfaction with the outcome (6). Objective metrics, such as the pink and white aesthetic scores, have been proposed for measuring aesthetic outcomes; however, they do not consider the patient's subjective appraisal of the therapy's success (7). While the patient's subjective assessment of a successful outcome and the clinician's objective evaluation may not always coincide, they should align when evaluating treatment's immediate and long-term effects.

Even though osseointegrated implants can be successfully maintained over an extended period, peri-implant mucosal recessions may significantly impact patient satisfaction and aesthetic outcomes. This factor and biological and clinical stability are critical for a favourable long-term prognosis. From a clinical perspective, peri-implant mucosal recessions are crucial for aesthetic results (8). Therefore, implant-supported restorations may require further corrective surgical therapy in regions where aesthetics are a top priority. Various factors, including the gingival phenotype (thick or thin), the presence of an inadequate width of attached/

keratinized mucosa, the height and thickness of the buccal or facial bone wall, a buccolingual malposition of the implant, the angle of the implant fixture, and the connection between the prosthesis and implant abutment, can contribute to the aetiology of peri-implant mucosal recessions (9). This research examines potential considerations for preventing soft tissue problems in implant-related treatment planning, highlighting the significance of soft tissue surrounding implants.

The success of dental implants depends on several factors, among which the stability and longevity of the soft tissue around them play a crucial role (10). While the implant fixture can provide a suitable anchor for the prosthetic tooth, the gums and surrounding tissue need to match the natural contours of the teeth and maintain their volume over time (11). This is especially true in cases where patients have suffered bone or tissue loss due to trauma, disease, or ageing (12). In actuality, using connective tissue graft in conjunction with immediate implant placement provided better support for the gingiva and proved more keratinised tissue surrounding the implant, whereas immediate implant placement alone created less aesthetic and less natural appearance without soft tissue management (13). Rather, the natural gingiva is supported by a connective tissue graft that uses the bone graft particle around the healing cap as a choice to provide more support for fresh socket. The safety seal technique has emerged as an innovative approach to increase width and vertical soft tissue on immediate dental implant placements. Using temporary support of healing caps, or "tent poles," anchored to the surrounding soft tissue, implantologists can create a scaffold for the surrounding tissue to grow and rebuild over time, resulting in a more stable and aesthetically pleasing implant restoration (14).

## MATERIALS AND METHODS

A prospective clinical study was conducted on ten patients (six male and four female) with immediate tooth extraction and implant placement. A total of 18 implants were placed. The study was conducted between February 2022 and September 2025, strictly adhering to the Declaration of Helsinki. Informed consent was obtained from each participant.

Before the non-restorable tooth/teeth extraction, injection needles and trans gingival probing methods were used to evaluate the gingiva's thickness at the teeth' buccal surface. Only a thin gingival thickness biotype ( $\leq 2$  mm) was included in this study. With the preservation of the socket and thin ridge, the teeth were atraumatically extracted, and the socket was curetted to remove any chronically infected tissue, then irrigated with chlorhexidine 0.12%. The implant site was then prepared according to the manufacturer's instructions and the G-DIFF ACH MEDICAL dental implant was

Gingival Thickness	Cases	Mean	Median	Standard Deviation	p-value
Before	18	1.311	1.3	0.256	< .00001
After six months	18	3.916	4.0	0.521	

**Tab. 1** Clinical gingival height measurement.

Gingival Thickness	Cases	Mean	Median	Standard Deviation	p-value
Before	18	1.93	1.95	0.287	< .00001
After six months	18	4.266	4.3	0.444	

**Tab. 2** Clinical thickness of keratinized gingival measurement

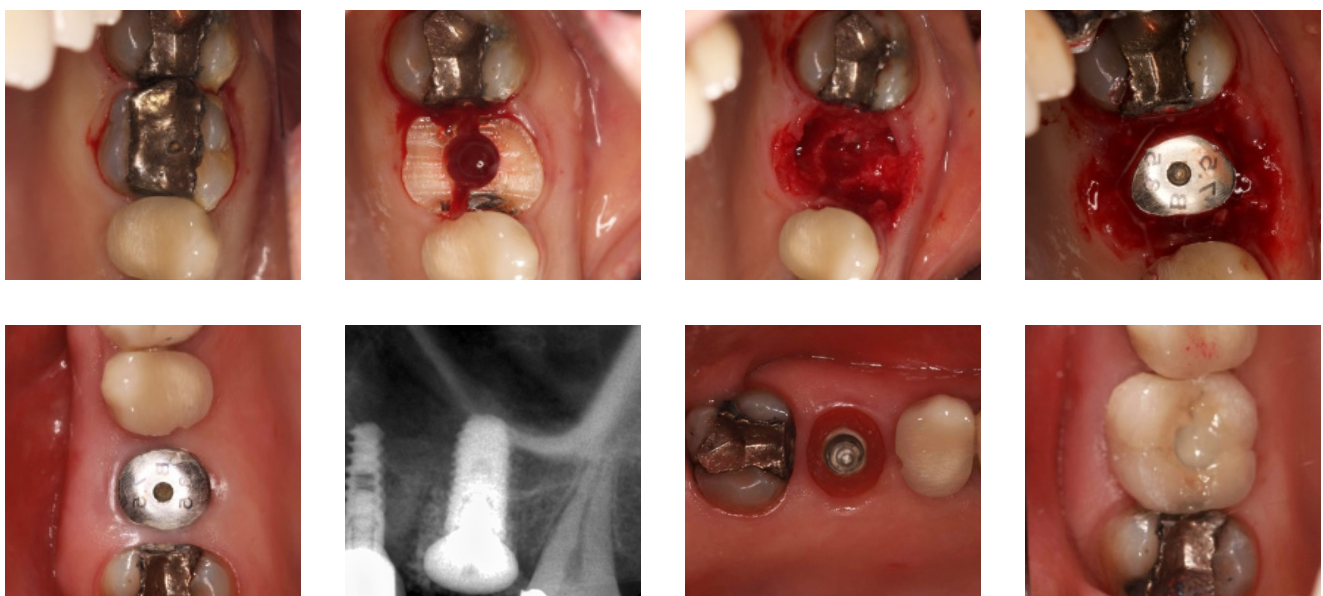
inserted subcrustal and sub-gingivally in an optimal palatal position of about 5 mm. A healing cap was inserted over the implants, with a gingival height of about 5 mm or more. It was crucial to ensure the healing abutment was positioned correctly without contact with the socket walls to avoid complications. Bone substitute particles (B-TCP and BCP Medbone®) mixed with autogenous bone were used to fill the gaps around the implant and surrounding socket. The space between the healing cap and soft tissue was over-augmented with bone particles, aiming to stabilize the gingival tissue in position. After suturing, any exposed bone particles were covered with a protective layer of gum barrier for about 24 hours.

**RESULTS**

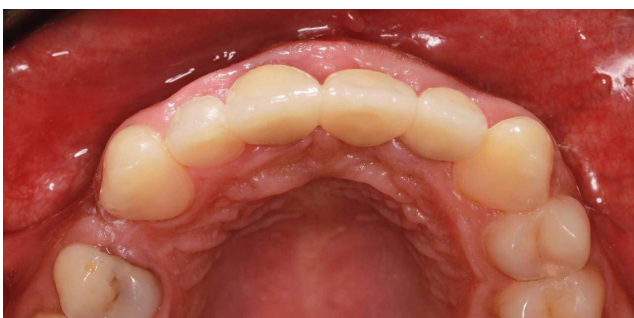
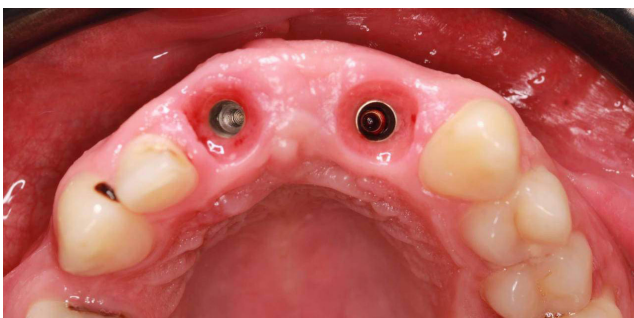
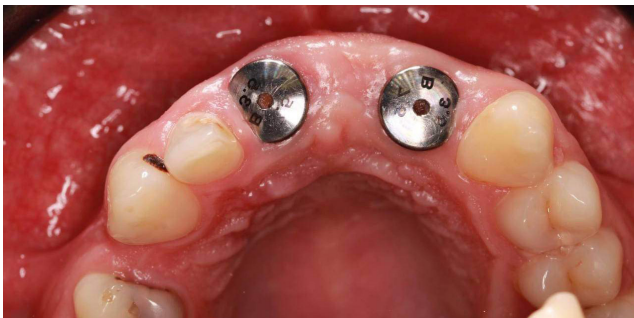
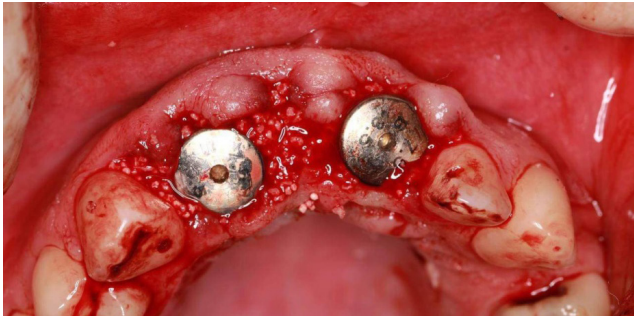
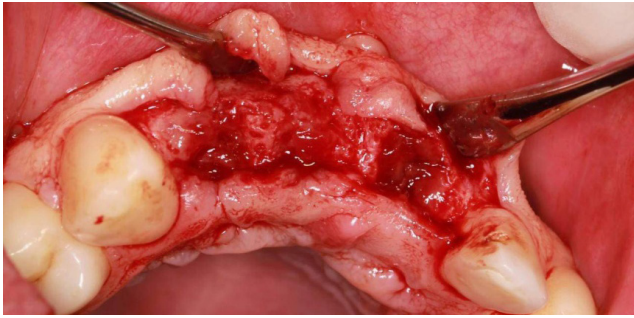
The clinical gingival height after six months remained stable, with an excellent aesthetic appearance. The gingival height significantly increased compared to pre-extraction measurements, with an average post-extraction gingival height of 3.916 mm (±0.521) compared to 1.311 mm (±0.256) pre-extraction. The gingival thickness demonstrated significant soft tissue growth surrounding the implants in dental sockets' immediate placement. The keratinized gingival tissue

growth was more robust than the pre-extraction state, as shown in Table 1.

The study showed positive results of the increase in the width of keratinized gingiva around dental implants, especially in the scenario where immediate implant placement was done after natural tooth extraction. After six months, the keratinized gingiva formed had gained a satisfactory thickness and stability, which are essential factors determining implant-retained prostheses' success. This improved gingival tissue not only improved the esthetic but also provided a thick layer of protection against possible peri-implant infections, keeping the well-being of the soft tissues in mind. In addition, the results showed that the cemented and screw-type crown restorations preserved this newly developed gingival thickness after loading, which meant that the changes in the soft tissue during the initial healing period were long-term reversible. This is especially so where there is the need to retain the shape of the gums for functional as well as cosmetic purposes in a clinical environment. As depicted in the data presented in Table 2, it is possible to conclude that the applied technique contributes to the increase in the width and stabilization of keratinized gingiva, contributing to the increased success of dental implants in aesthetics and durability (fig. 1, 2).



**Fig. 1** Dental implants replacement of teeth no. 16 placed with safety seal.



**Fig. 2** Dental implants replacement of teeth no. 1, 11 and 12 placed with safety seal.

## DISCUSSION

Immediate implant placement showed promising outcomes regarding tissue changes and implant survival when proper socket sealing was done through socket seal abutments, customized healing abutments, and homologous bone membranes. The findings of the present study in terms of changes in the dimensions of keratinized gingiva after immediate implant placement are well aligned with the previous research that has underlined the role of peri-implant soft tissue as a factor in the success of implant therapy. The improvements achieved in this study showed that by placing bone grafts around the implant and healing caps at the time of tooth extraction, it is possible to achieve the required increase in soft tissue thickness and height necessary for implant stability and esthetics in the long term.

Previous studies have also pointed out that adequate keratinized mucosa around the implants is essential in maintaining peri-implant tissues. For instance, Gamborena et al. (4), found out that due to a lack of keratinized mucosa, high plaque formation and inflammation occur around the implants, which may lead to implant instability and recession or failure. The above findings are in concordance with the present study as the new keratinized gingiva formed around the implants was esthetically acceptable from an esthetic point of view and biomechanically stable for the overall success of the implant treatment (15). The method used in this study involved positioning the bone grafts around the implant and using the healing caps aimed at augmenting the dimensions of the peri-implant soft tissues in terms of thickness and height. This approach is compatible with the new standards for implant success that are not only the implant success but the patient's perceived esthetic and functional enhancement (7,16). This concept has evolved from the previous conception of osseointegration to encompass the aesthetics of the soft tissues surrounding the implant because these tissues are critical in determining the patient's satisfaction and the implant's stability.

The findings of this study also confirmed stable gingival tissue levels in both cemented and screw-type crowns, and this is due to successful soft tissue augmentation from the bone grafts. This consideration is crucial because peri-implant mucosal recessions are a prevalent problem in implant dentistry, leading to esthetic failure and patients' dissatisfaction (16,17). In this case, the technique used in this study enhances the dimensional gain and the structural integrity of the inter-implant tissue that can provide a stable soft tissue margin around the implant neck, thus preventing recession and enhancing the long-term esthetic outcomes of the implant. Besides, the increase in gingival height and thickness, evident in this study,

may be due to the site preparation and appropriate use of bone substitute materials that support soft-tissue growth. This approach has been endorsed Jiang (18), who opined that there is a need to be very cautious during implant placement to avoid damaging the soft tissues or leaving them recessed but instead strive to have them enhanced in order to get the best aesthetic outcome, particularly in the anterior maxilla where aesthetics are of paramount importance. Another significant implication of the findings is that patient variables such as gingival phenotype affected the procedure's outcome. The study was carried out on patients with a thin gingival biotype, which is always at higher risk of developing recession and achieving poor aesthetics without contouring. The positive outcomes of this study confirm that the technique used was efficient in managing the difficulties related to thin facial bony structures, hence offering stable and esthetically favourable peri-implant soft tissues. The results of this study also confirm the necessity of considering patients' satisfaction when evaluating the success of implantations. According to the study conducted by Kan et al. (19), there is often a difference between the clinician's view and that of the patient with regard to the effectiveness of the treatment. This could have resulted in higher patient satisfaction because the gingival thickness and height were maintained as was observed in this study, and the outcome would have met the patient's expectations of a natural-looking restoration (20). This synchrony of clinical and patient perception of implant treatment success may be necessary for the overall understanding of implant dentistry and highlights that implant treatment planning should focus on the function and aesthetics of the implant-supported restoration (17). Another critical aspect of the study is the effectiveness of the surgical treatment, which depends on the patient's characteristics and the main focus on gingival phenotype. The study aimed to include only those patients with a thin gingival biotype, which is more prone to recession and cannot provide an excellent esthetic outcome without surgery. The findings of this study indicate that the technique successfully overcame the hurdles characteristic of thin bony ridges, resulting in predictable and esthetic peri-implant soft tissues. The results of this study also suggest that self-reported patient satisfaction should be included in the evaluation of implant outcomes. According to Bakkali et al. (21), there could be a gap between the clinician's perception of treatment outcomes and the patient's view. The gingival thickness and height were well maintained in the present study, resulting in increased patient satisfaction, as the final result would have aligned with the patient's perception of an ideal aesthetic outcome. The perception of the success of the implant treatment from the clinical and patient perspectives may be better for implant dentistry,

which aims to achieve functional and aesthetically acceptable results.

## CONCLUSION

This research shows that the early placing of bone grafts around dental implants and healing caps after tooth extraction increases the thickness and height of the soft tissues around the implants, thus providing better aesthetic and functional results. The technique effectively creates stable keratinized gingiva, essential to the implant treatment's overall success and satisfaction.

## REFERENCES

- Sartoretto SC, Shibli JA, Javid K, Cotrim K, Canabarro A, Louro RS, Lowenstein A, Mourão CF, Moraschini V. Comparing the long-term success rates of tooth preservation and dental implants: a critical review. *Journal of Functional Biomaterials*. 2023 Mar 3;14(3):142.
- Alghamdi HS, Jansen JA. The development and future of dental implants. *Dental materials journal*. 2020 Mar 27;39(2):167-72.
- Sailer I, Barbato L, Mojon P, Pagliaro U, Serni L, Karasan D, Cairo F. Single and partial tooth replacement with fixed dental prostheses supported by dental implants: A systematic review of outcomes and outcome measures used in clinical trials in the last 10 years. *Clinical oral implants research*. 2023 May;34:22-37.
- Gamborena I, Sasaki Y, Blatz MB. Predictable immediate implant placement and restoration in the esthetic zone. *Journal of Esthetic and Restorative Dentistry*. 2021 Jan;33(1):158-72.
- Cosyn J, Wessels R, Garcia Cabeza R, Ackerman J, Eeckhout C, Christiaens V. Soft tissue metric parameters, methods and aesthetic indices in implant dentistry: A critical review. *Clinical Oral Implants Research*. 2021 Oct;32:93-107.
- Ghahroudi AA, Rohn AR, Shamshiri AR, Samiei N. Does timing of implant placement affect esthetic results in single-tooth implants? A cohort evaluation based on mPES. *Journal of Esthetic and Restorative Dentistry*. 2020 Oct;32(7):715-25.
- Hamilton A, Gonzaga L, Amorim K, Wittneben JG, Martig L, Morton D, Martin W, Gallucci GO, Wismeijer D. Selection criteria for immediate implant placement and immediate loading for single tooth replacement in the maxillary esthetic zone: A systematic review and meta-analysis. *Clinical oral implants research*. 2023 Sep;34:304-48.
- Kumar H, Kalyani P, Shifa Balkhis A, Janardanan K. CHANGING TRENDS IN IMMEDIATE LOADING OF IMPLANTS.
- Lumbau AI, Meloni SM, Tallarico M, Melis L, Spano G, Baldoni E, Koshovari A, Pisano M. Implant Placement Following Crestal Sinus Lift with Sequential Drills and Osteotomes: Five Years after Final Loading Results from a Retrospective Study. *Journal of Functional Biomaterials*. 2021 Feb 4;12(1):10.
- Levin M, Spiro RC, Jain H, Falk MM. Effects of titanium implant surface topology on bone cell attachment and proliferation in vitro. *Medical Devices: Evidence and Research*. 2022 Apr 26:103-19.
- Stepanovska J, Matejka R, Rosina J, Bacakova L, Kolarova H. Treatments for enhancing the biocompatibility of titanium implants. *Biomedical Papers of the Medical Faculty of Palacky University in Olomouc*. 2020 Mar 1;164(1).
- El Biary SO, Atef M, Abdelaziz MS, Khashaba M. Guided immediate implant with and without using a mixture of autogenous and xenogeneic bone grafts in the dental esthetic zone. A randomized clinical trial. *BMC Research Notes*. 2023 Nov 13;16(1):331.
- Abd el Aziz N, Abd El-Rahman A, El-Barbari A, Elarab A. The esthetic effect of connective tissue graft addition around immediate dental implants in the esthetic zone: A randomized clinical trial. *J Osseointegr [Internet]*. 2021 Nov. 24 [cited 2025 Jul. 14];14(2):97-106. Available from: <https://www.journalofosseointegration.eu/jo/article/view/468>
- Hu KS, Li H, Tu YK, Lin SJ. Esthetic results of immediate implant placement in extraction sockets with intact versus deficient walls. *Journal of dental sciences*. 2021 Jan 1;16(1):108-14.
- Overmann AL, Aparicio C, Richards JT, Mutreja I, Fischer NG, Wade SM, Potter BK, Davis TA, Bechtold JE, Forsberg JA, Dey D. Orthopaedic osseointegration: Implantology and future directions. *Journal of Orthopaedic Research*. 2020 Jul;38(7):1445-54.
- Guo T, Gulati K, Arora H, Han P, Fournier B, Ivanovski S. Race to invade: Understanding soft tissue integration at the transmucosal region of titanium dental implants. *Dental Materials*. 2021 May 1;37(5):816-31.
- Ragucci GM, Elnayef B, Criado-Cámara E, Del Amo FS, Hernández-Alfaro F. Immediate implant placement in molar extraction sockets: a systematic review and meta-analysis. *International journal of implant dentistry*. 2020 Dec;6:1-2.
- Jiang X, Di P, Ren S, Zhang Y, Lin Y. Hard and soft tissue alterations during the healing stage of immediate implant placement and provisionalization with or without connective tissue graft: A randomized clinical trial. *Journal of clinical periodontology*. 2020 Aug;47(8):1006-15.
- Kan JY, Rungcharassaeng K, Deflorian M, Weinstein T, Wang HL, Testori T. Immediate implant placement and provisionalization of maxillary anterior single implants. *Periodontology 2000*. 2018 Jun;77(1):197-212.
- Puisys A, Auzbikaviciute V, Vindasiute-Narbutė E, Pranskunas M, Razukevicius D, Linkevicius T. Immediate implant placement vs. early implant treatment in the esthetic area. A 1-year randomized clinical trial. *Clinical Oral Implants Research*. 2022 Jun;33(6):634-55.
- Bakkali S, Rizo-Gorrita M, Romero-Ruiz MM, Gutiérrez-Pérez JL, Torres-Lagares D, Serrera-Figallo MÁ. Efficacy of different surgical techniques for peri-implant tissue preservation in immediate implant placement: a systematic review and meta-analysis. *Clinical Oral Investigations*. 2021 Apr;25:1655-75.